

**EVERYTHING YOU WANTED TO  
KNOW ABOUT ORAL SURGERY BUT  
WERE AFRAID TO ASK PART 2**

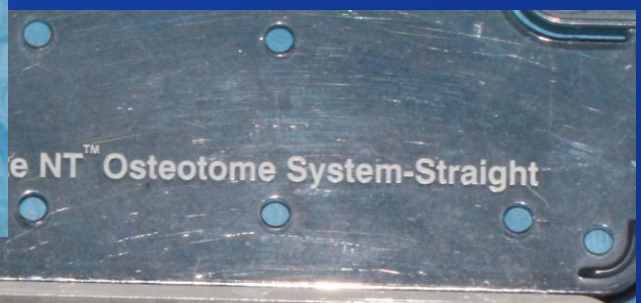
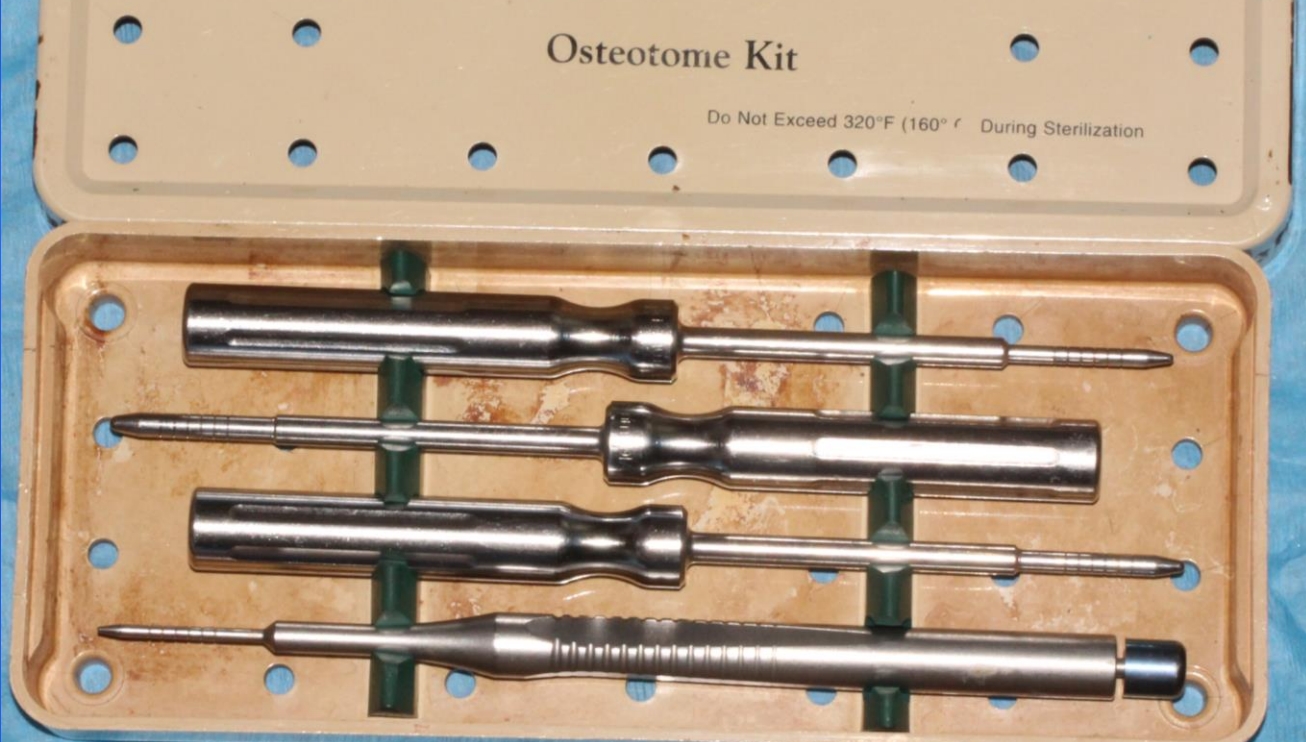**RONALD P MORRIS, DDS**  
**Oral & Maxillo-facial Surgeon**  
**Downriver Surgery Center**  
**1823 Fort, Wyandotte, MI 48192**  
**734-285-2550 DRronoms@aol.com**  
**Website: [downriversurgery.com](http://downriversurgery.com)**

# Sponsors

- ❑ **Keystone Dental** (Tri-Max /TiLobe Maxx Implants)
- ❑ **Implant Direct** (Legacy Implants and abutments)
- ❑ **Patterson Dental** (sutures, blades, adhesives)
- ❑ **Geistlich Biomaterials** (Bio-Oss bone grafting materials)
- ❑ **Ivoclar/Vivadent** (Multilink Automix dual cure resin cement)
- ❑ **Contour Healer** (contoured healing abutments-PEEP)
- ❑ **Palisades Dental** (Impact Air 45 high speed handpieces)
- ❑ **Kerr** (Demi Ultra LED Ultracapacitor Curing Light System)
- ❑ **3M-ESPE** (Polycarbonate temporary crowns)
- ❑ **Salvin Dental Specialties** (instruments)

# Review of procedures:

- ▣ Extraction of Mandibular 1<sup>st</sup> molar and Immediate wide diameter implant and graft
- ▣ Extraction of Maxillary 1<sup>st</sup> molar and Immediate wide diameter implant with sinus lift and graft
- ▣ Extraction of Maxillary Central Incisor with Immediate implant, immediate abutment, immediate temporary, and socket graft
- ▣ Soft tissue uncovering of implant with insertion of custom abutment/temporary
- ▣ Soft tissue uncovering of implant with palatal roll connective tissue graft



# Impact Air 45



Palisades Dental LLC

[HOME](#)

[ABOUT US](#)

[PRODUCTS](#)

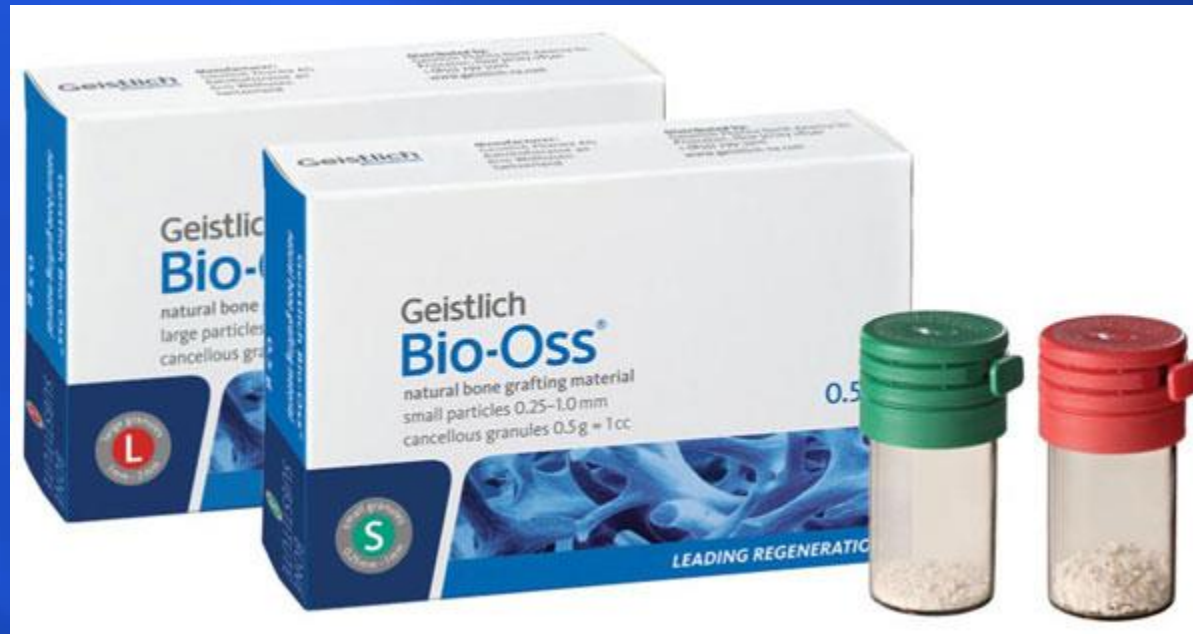[SALES](#)

[SUPPORT](#)

[CONTACT](#)



# Geistlich Bio-Oss






Smarter thinking. Simpler design.™

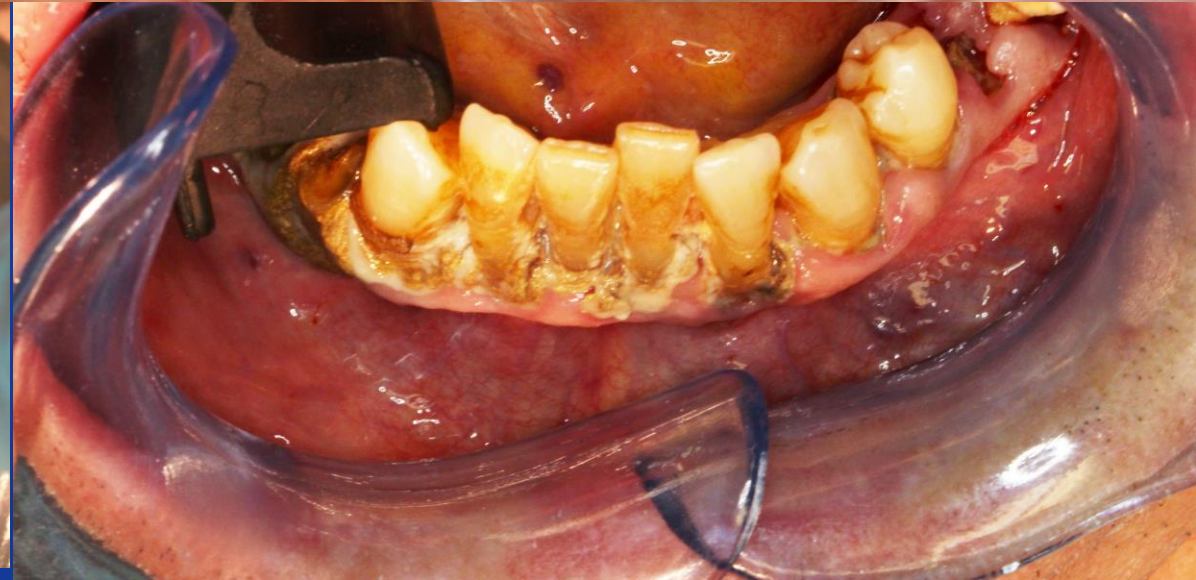
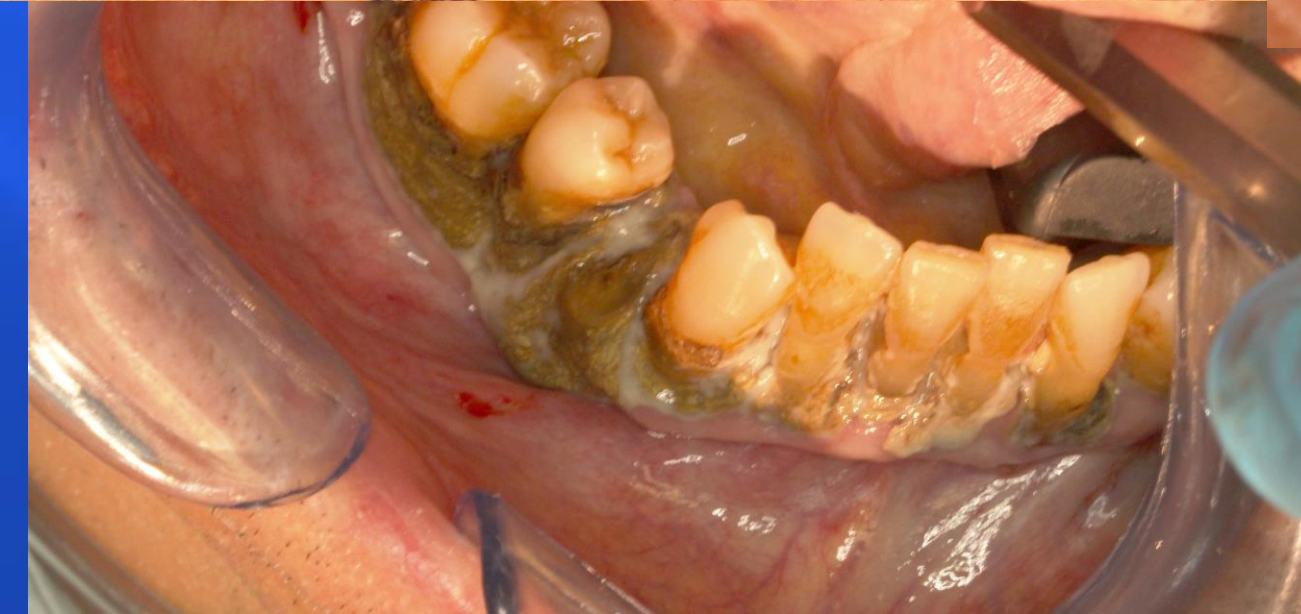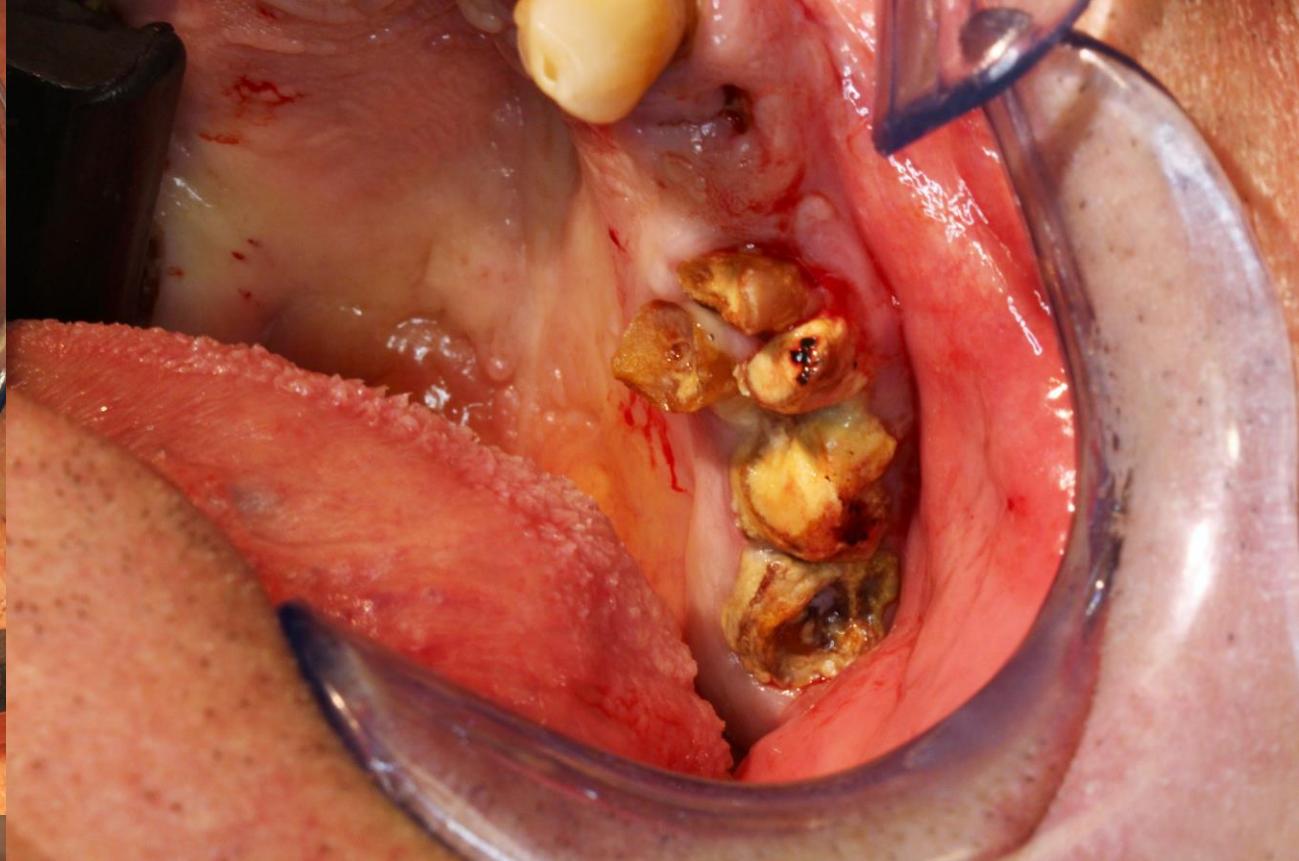
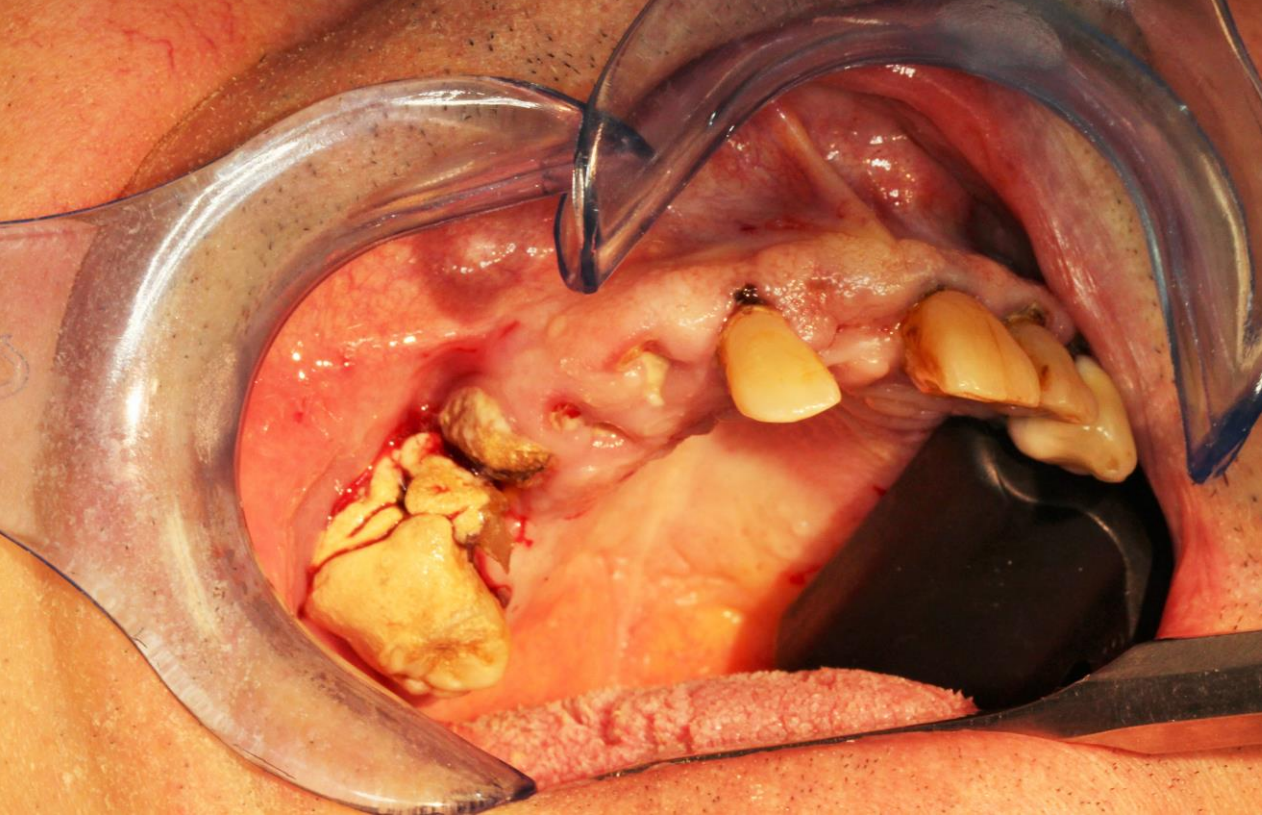
## Indication Specific Implant Options

TiLobeMAXX & Genesis



# Extraction of Mandibular 1<sup>st</sup> Molar with Immediate Implant

- ▣ Case selection: Ideal with no infection and intact buccal and lingual cortical plates
- ▣ No soft tissue defects
- ▣ Pre-operative x-rays; prefer 3D cone beam if possible but not mandatory
- ▣ Assess lingual undercut
- ▣ Medical risk factors: diabetes, smoker, heavy Etoh use, poor oral hygiene, and immune system disorders



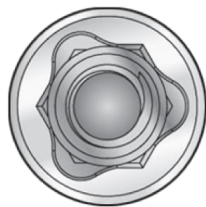


THE  
PERFECT  
SMILE

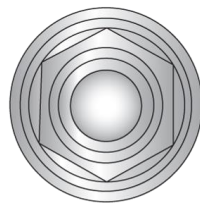


# MAX Implants

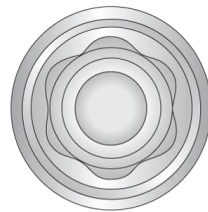
Keystone Dental Acquired Southern Implants in 2012




Internal Tri-Lobe



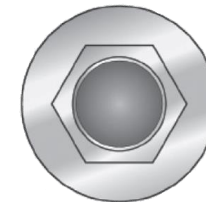
Internal Hexagon



Internal TiLobe



Internal Octagon/  
Morse Taper



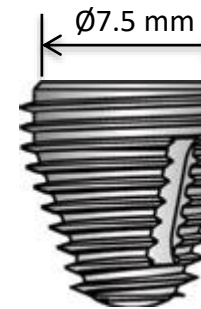
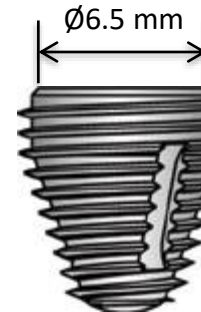
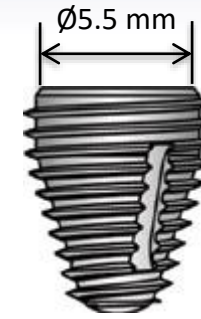
External Hexagon

# Immediate Placement Advantages

- Shorter treatment time - allows for immediate placement following extraction
- Fewer surgical procedures - minimizes the need for grafting, regenerating, implant placement protocol
- Wider implant design maximizes bone preservation
- Soft tissue preservation – improves emergence profile
- Reduced patient discomfort -
- Superior esthetic result – no food traps
- Patient satisfaction – reduces time and costs

# TiLobeMAXX<sup>®</sup> Connection

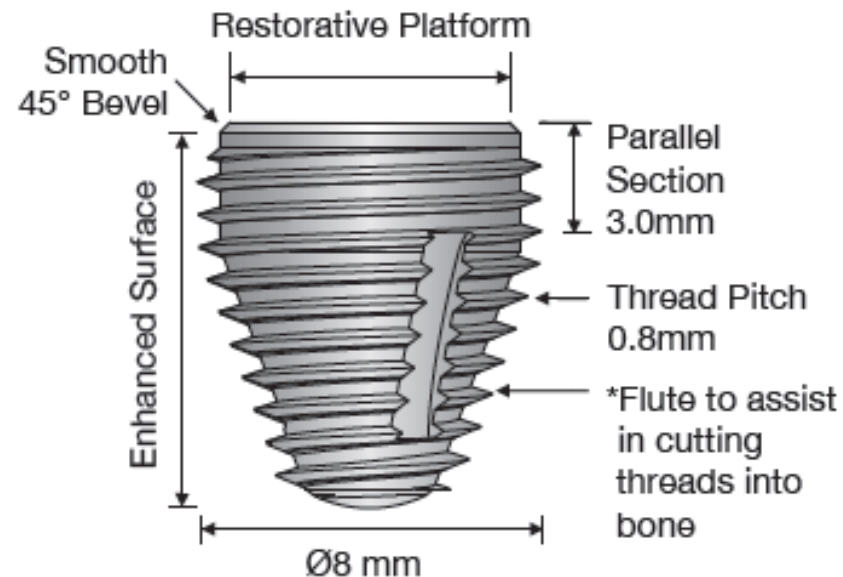
- MAX-TL  $\varnothing$ 7.0 mm Implants feature a  $\varnothing$ 5.5 mm platform. Prima (5.0) or Genesis (5.5/6.5) abutments are available in a flare 6.0 mm.
- MAX-TL  $\varnothing$ 8.0 mm Implants feature a  $\varnothing$ 6.5 mm platform. Prima (5.0) or Genesis (5.5/6.5) abutments are available in a flare of 6.0 mm.
- MAX-TL  $\varnothing$ 9.0 mm Implants feature a  $\varnothing$ 7.5 mm platform. Separate abutments are available in a flare of 7.0 mm. **Can also be used on the  $\varnothing$ 8.0 mm implants**



# TiLobeMAXX Dental Implant System

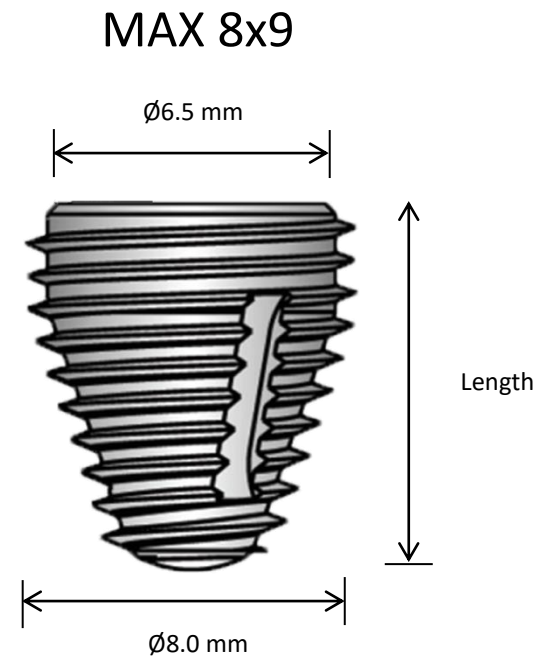
## Design Features

The MAX Implants features a body with a larger-than-conventional diameter to fill a molar site, ultimately achieving primary stability by engaging the perimeter of the bony wall. The MAX-TL Implant has a tapered body, an enhanced surface and is designed to fit the natural shape of the molar socket. The MAX-TL Implant provides an optimal fit in the multi-rooted immediate extraction site, minimizing bone loss and reducing treatment time.




# TiLobeMAXX Dental Implant System

- 7 mm, 8 and 9 mm diameter implant
- Greater tapered body
  - Engages the apical intra-radicular bone
  - Fits tapered socket
  - Avoids lateral sinus perforation
  - Avoid adjacent roots
  - Conservation of bony walls
  - Superior primary stability

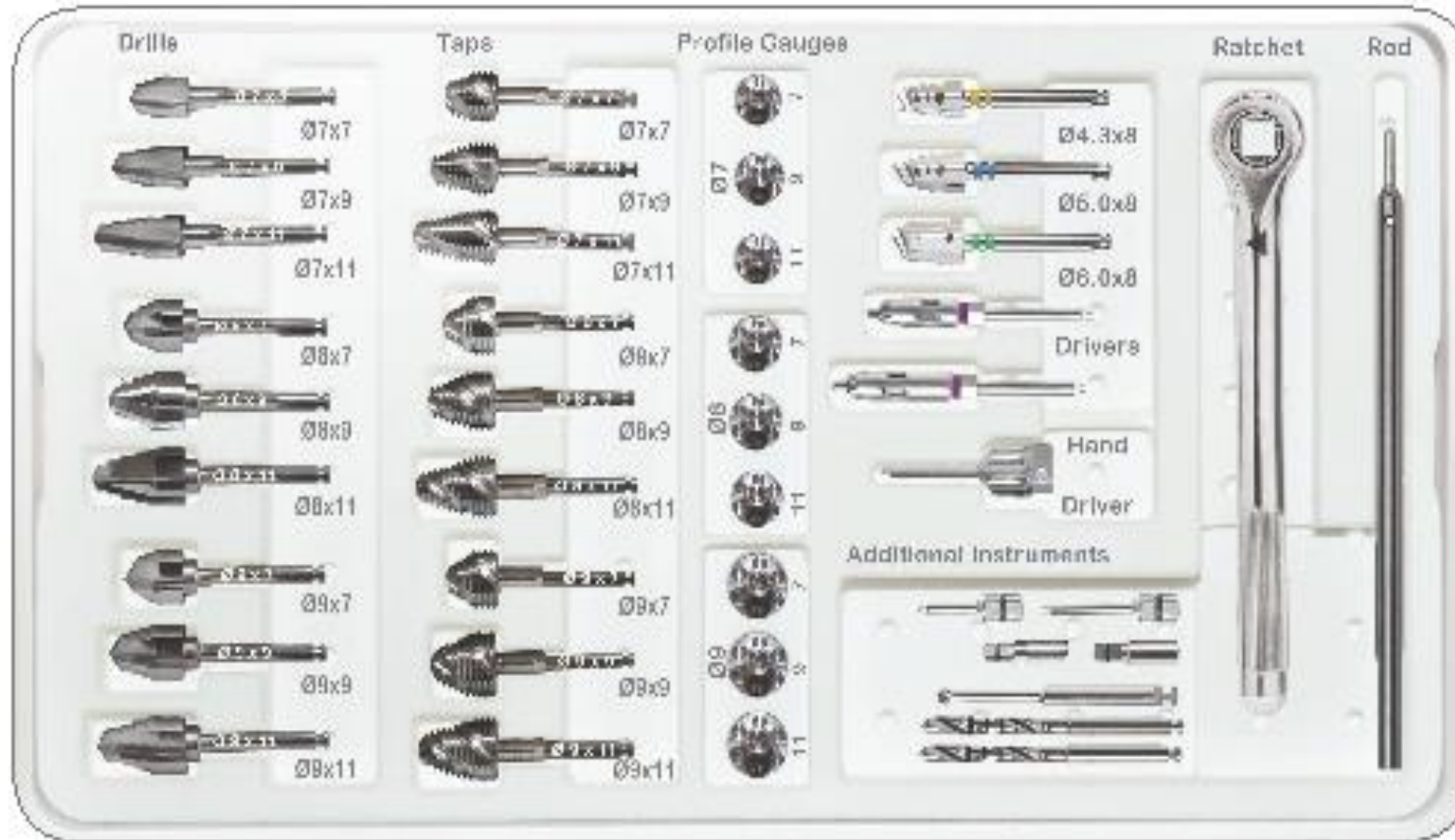


# Enhanced Surface Technologies


- Proprietary surface similar to SLA
- Consistent, well-controlled process
- Performance well-documented over 13 years in peer-reviewed literature
- *Clinical Oral Implants Research Journal*, Volume 13:86-93
- *Clinical Implant Dentistry and Related Research*, 2003; Volume 5:3m



# MAX Dental Implant System



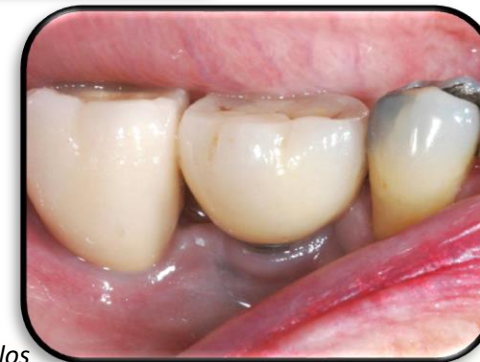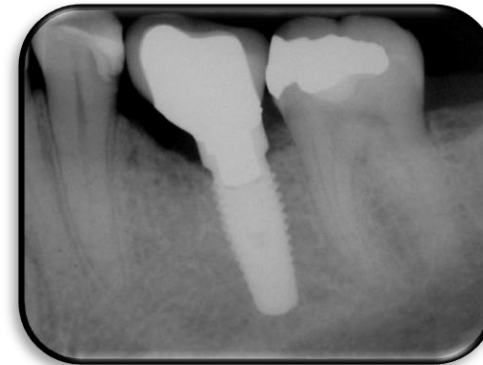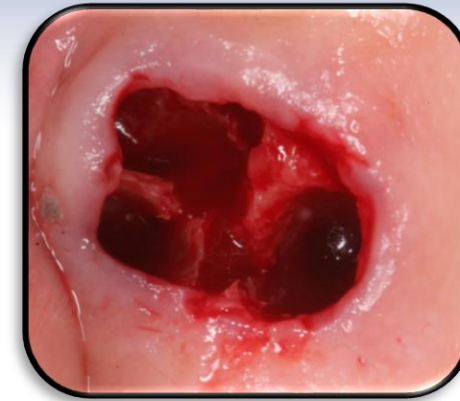# MAX Dental Implant System



# Molar Extraction Socket Challenges

Placing a regular diameter implant in existing root socket:

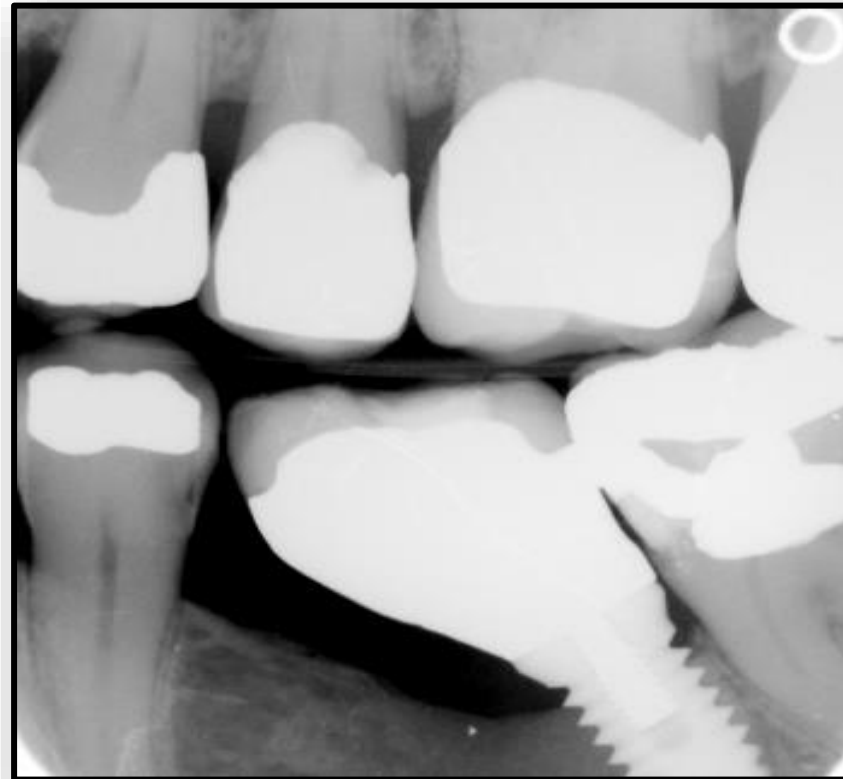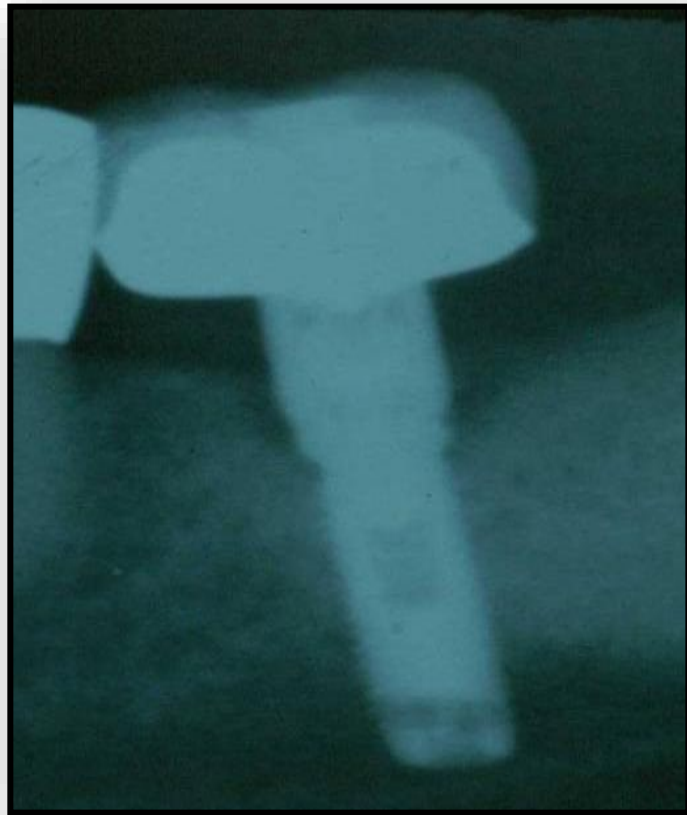
- Multi-rooted extraction socket is often too large to accommodate a regular size implant
  - Stability – off-angle loading
  - Compromised emergence profile
- Grafting and delayed implant placement is often required
  - Patient does not return
  - Time
- Single root placement might require surgical and prosthetic compromises
  - Food trap
  - Cantilever effect



*Image compliments of Dr. Costa Nicolopoulos*

# Standard Dental Implant Systems

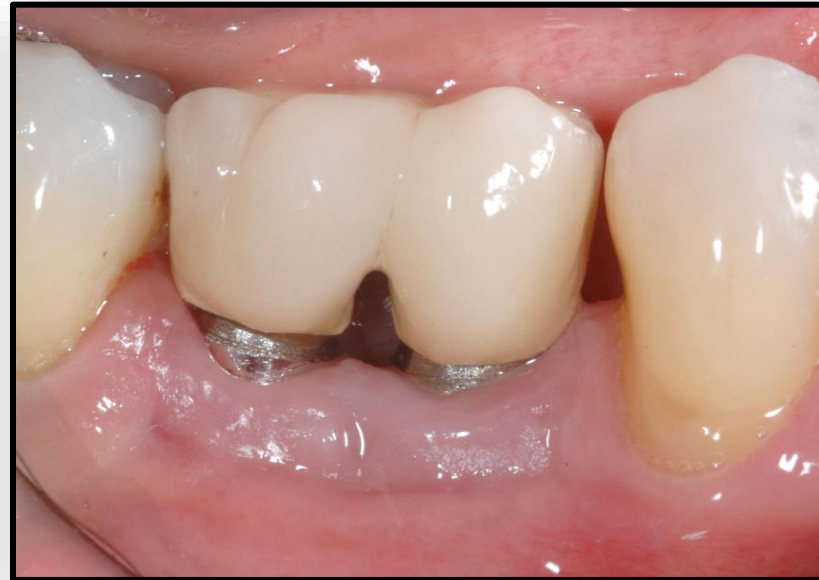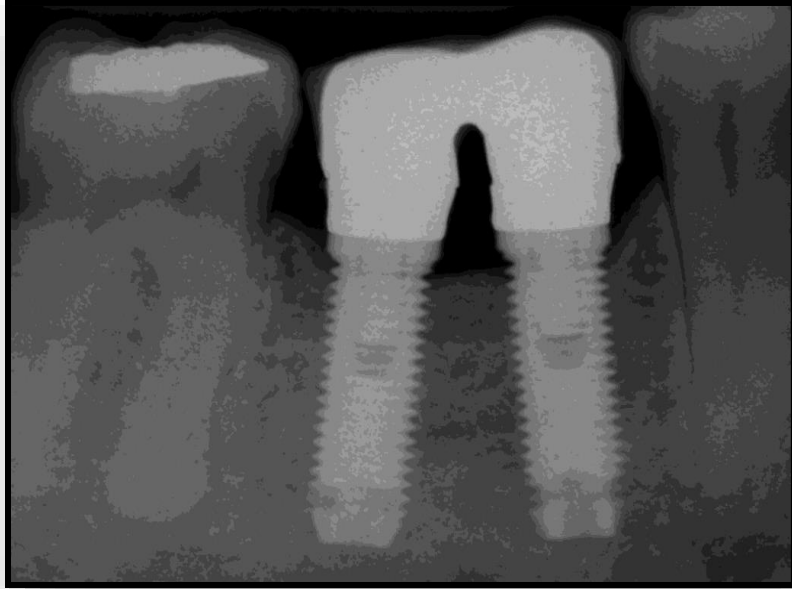
## Clinical Challenges



*Courtesy of Stuart Graves, OMS, Rockville, MD*

# Standard Dental Implant Systems

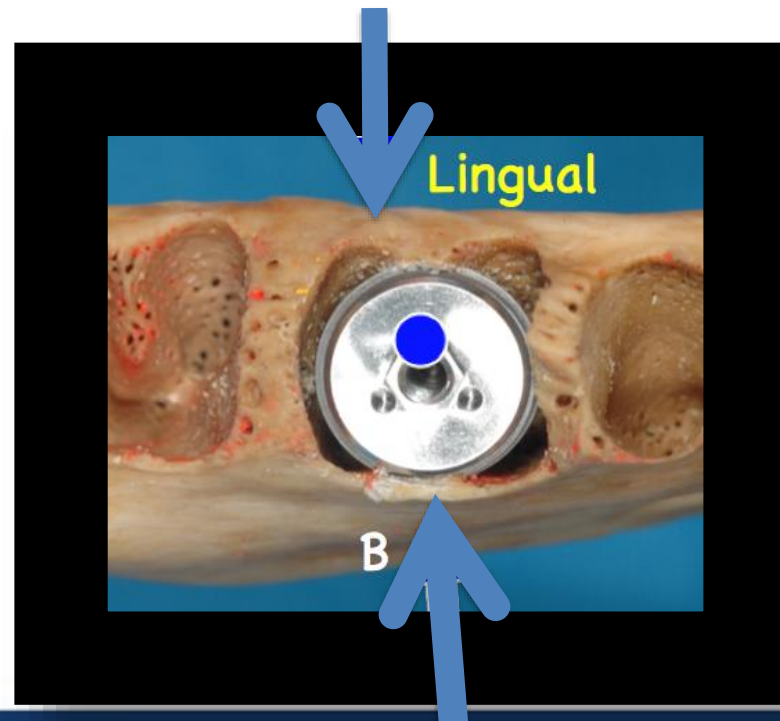
## Clinical Challenges



# Tri-MAX Dental Implant System

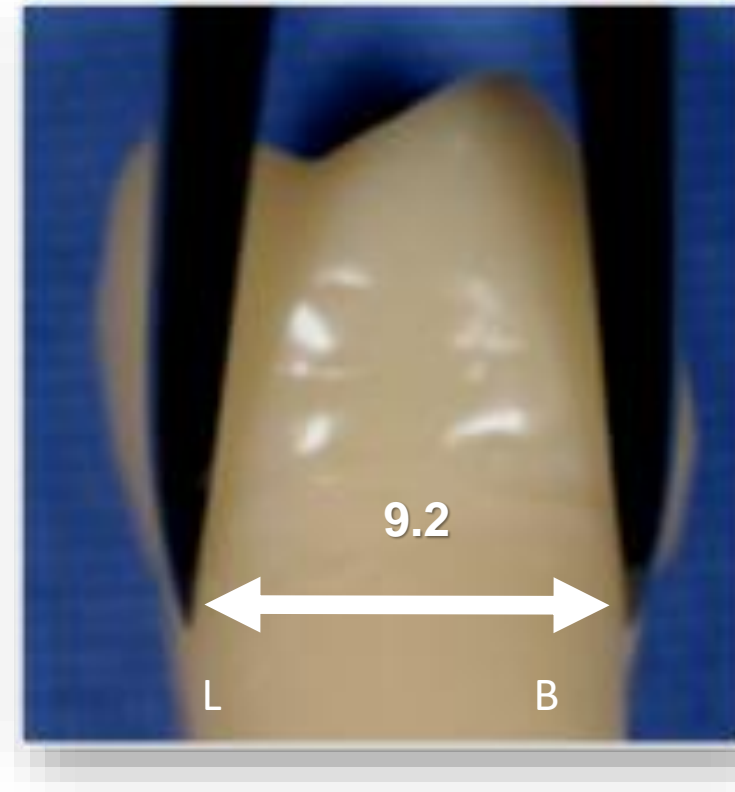
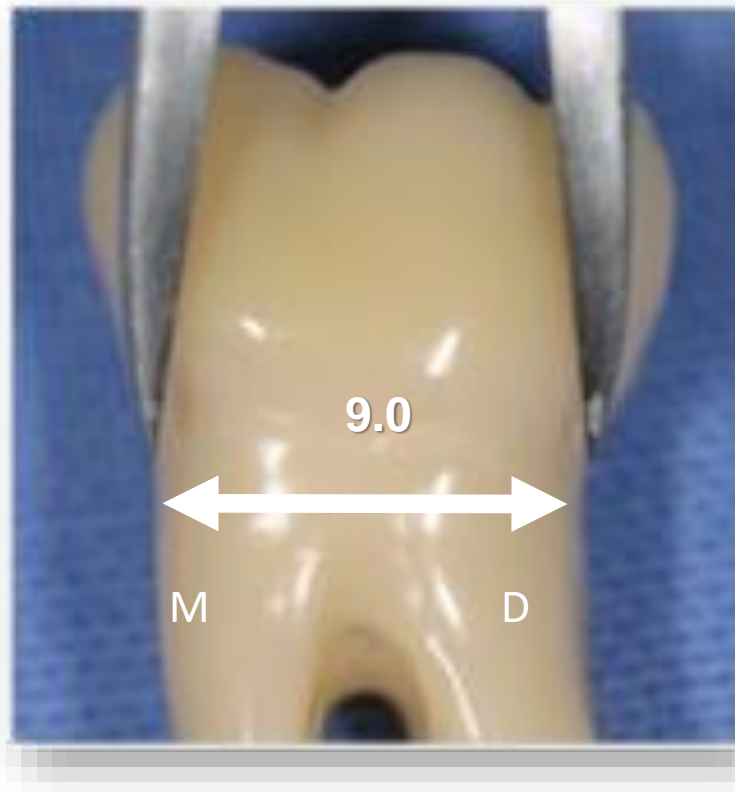
## Clinical Suggestions

- In the Mandibular posterior it is recommended for placement to be **sub-crestal 2.0 mm, towards the lingual, and 2.0 mm away from the buccal wall** for bone to cover the threads



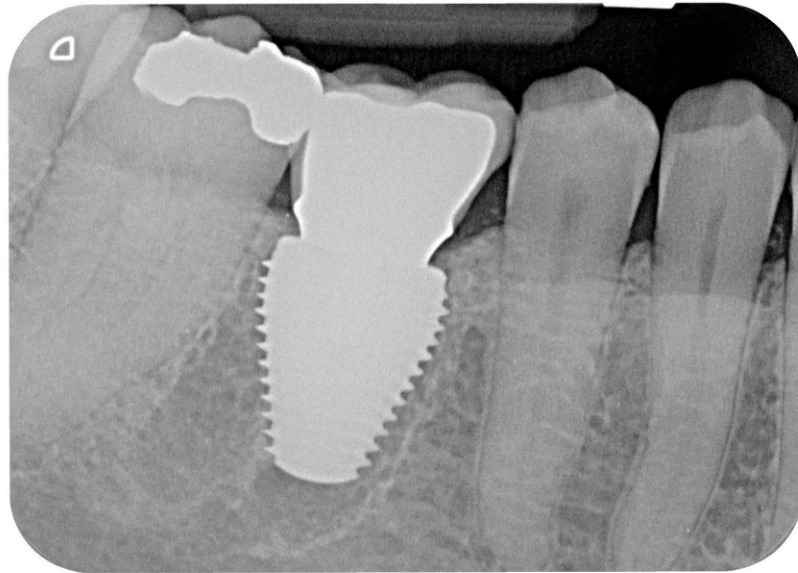
# MAX Dental Implant System

## Implant Sizing - Mandibular First Molar

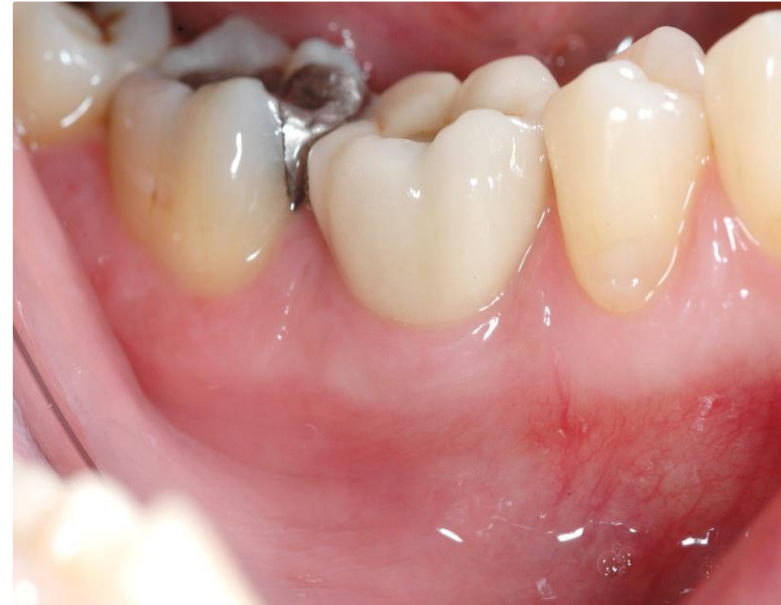

# MAX Dental Implant System

## Clinical Solutions

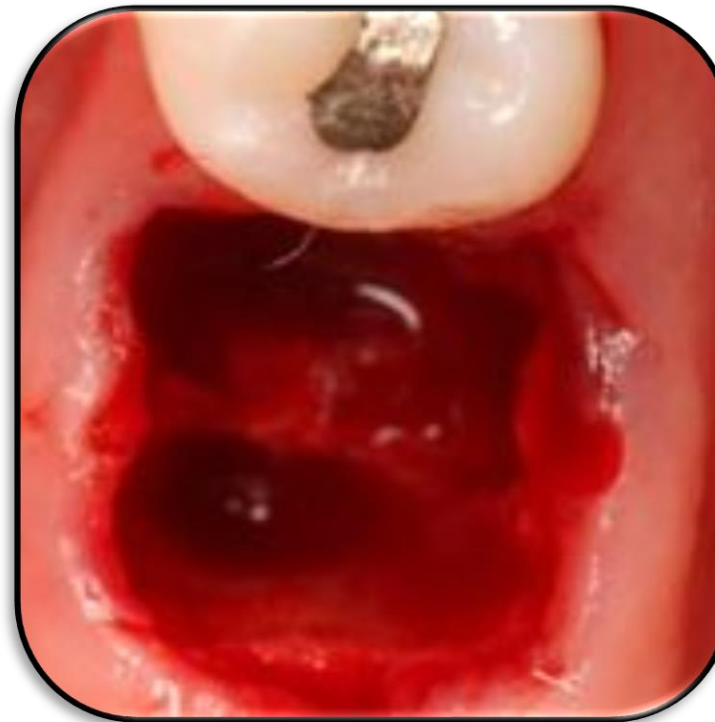
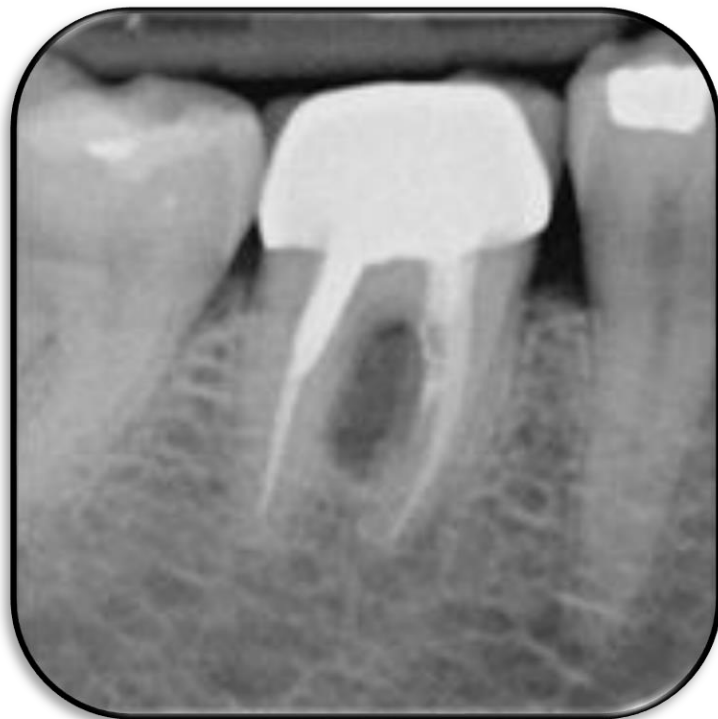
Mandible MAX  
2 years post-op



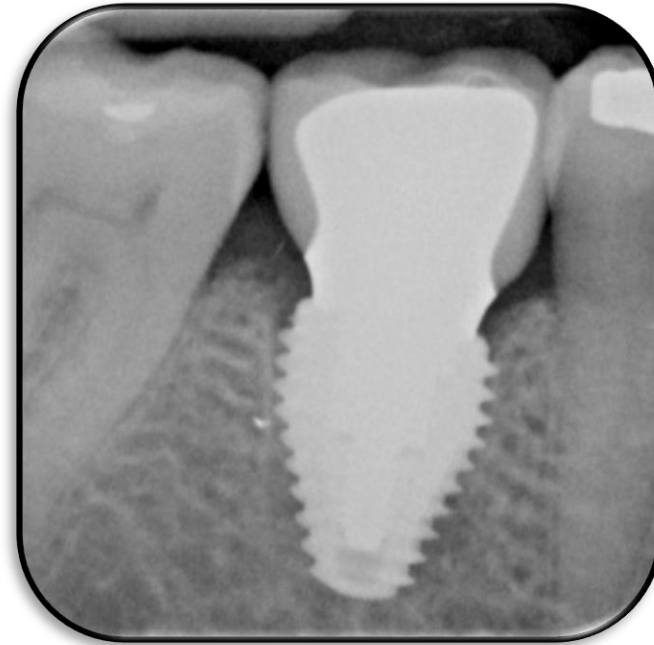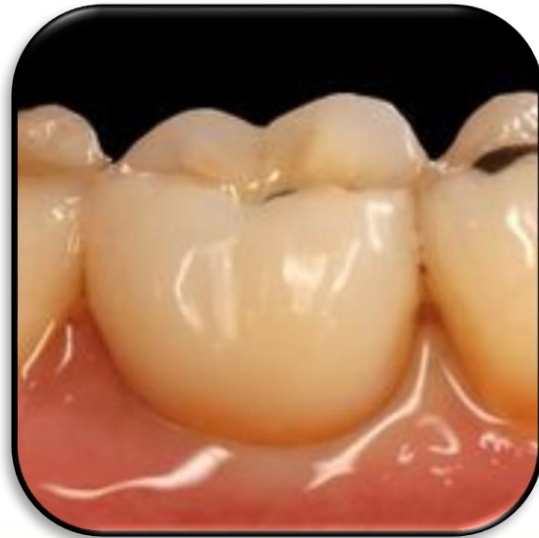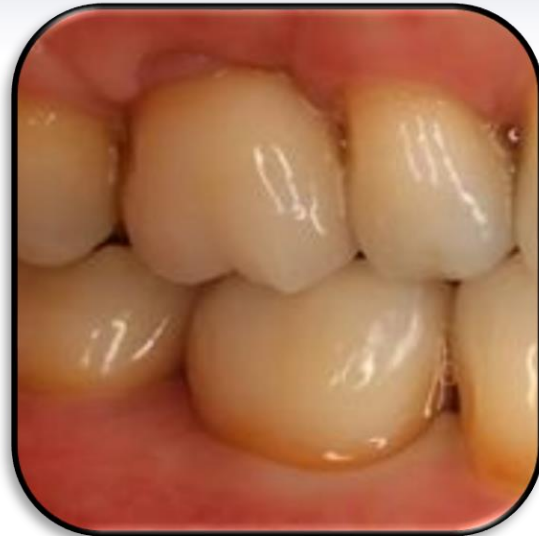Courtesy of Dr. A. Hattingh, Perio

# MAX Dental Implant System



Courtesy of Dr. Rick Smith  
The NY Center For Specialized Dentistry NYC, NY

# MAX Dental Implant System



Courtesy of Dr. Rick Smith  
The NY Center For Specialized Dentistry NYC, NY

# Prosthetics for the TiLobeMAXX


## Impression Posts

- Closed/open Tray, except 9.0mm
- Matches the flare of the healing abutment
- Flare – 7.0 mm



# Final Abutment for TiLobeMaxx Implant

- Anatomical contours
- Natural emergence profile diameters for a natural esthetic emergence through the soft tissue
- Supports the inter-dental papilla
- Available in 7.0 mm flare



# TiLobeMAXX®

Keystone Dental's MAX-TL® implants incorporate TiLobe® Technology, a patented internal 6-lobed connection that provides a stable foundation for life-long esthetic results by honoring the principles of biology and bio-mechanics.

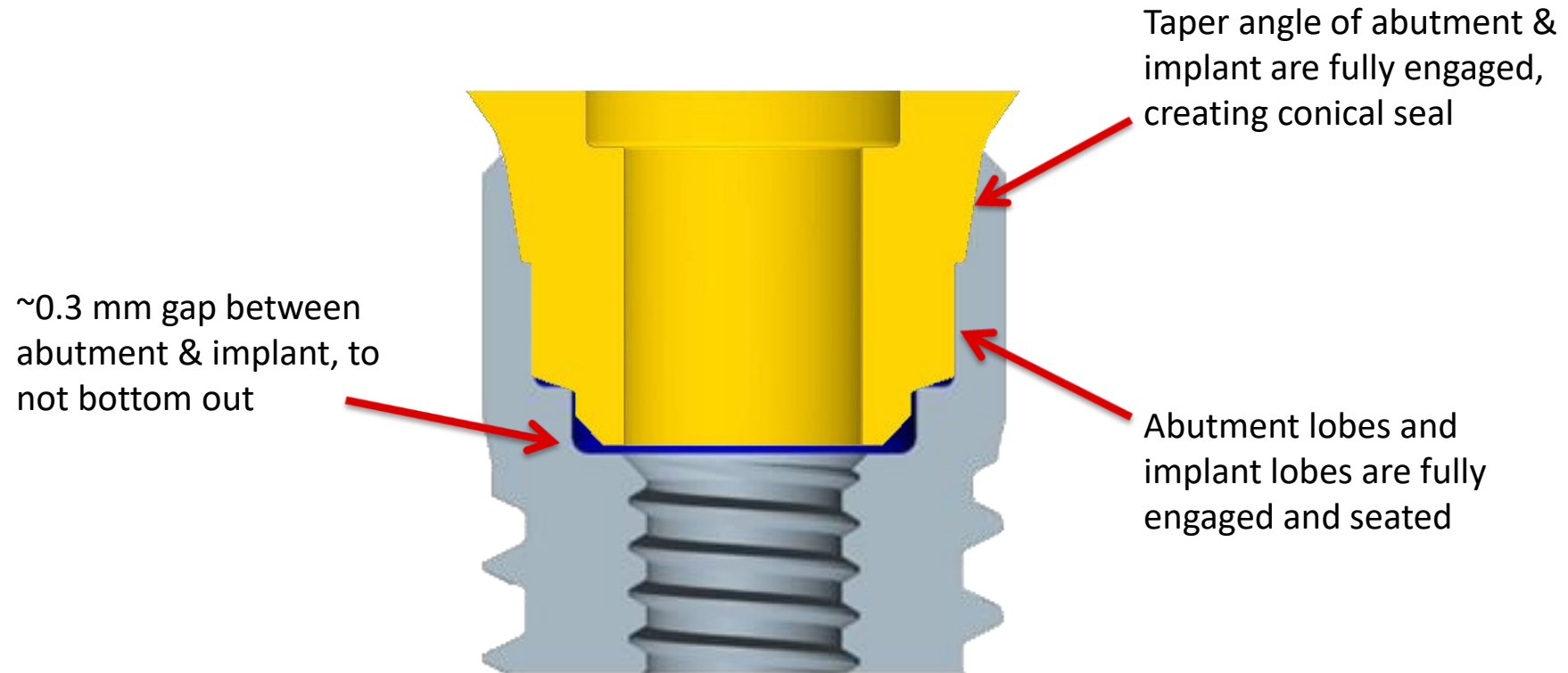
## Synergy Through Strength And Stability

- **Self-sealing coronal taper**
- **6 lobe internal design**
- **Tight tolerances**




# Genesis Implant System

## Correct Seating Of TiLobe



# MAX Dental Implant System



- Allows for platform switching

# Immediate Placement Advantages-Review

- Shorter treatment time - allows for immediate placement following extraction
- Fewer surgical procedures - minimizes the need for grafting, regenerating, implant placement protocol
- Wider implant design maximizes bone preservation
- Soft tissue preservation – improves emergence profile
- Reduced patient discomfort -
- Superior esthetic result – no food traps
- Patient satisfaction – reduces time and costs

# Extraction of Mandibular 1<sup>st</sup> Molar with Immediate Implant

- ▣ Preoperative antibiotics-ideal 5 days of Keflex 500mg QID or Cleocin 150mg QID
- ▣ Preoperative Motrin 800mg or plain Tylenol 500mg
- ▣ Peridex or comparable preoperative mouth rinse
- ▣ Sedation orally or IV if warranted
- ▣ Opposing arch impression in alginate
- ▣ Preoperative photographs and shade selection

# Extraction of Mandibular 1<sup>st</sup> Molar with Immediate Implant

- ▣ Atraumatic extraction and flapless (release of papilla only if necessary, for elevator)
- ▣ Plan on high speed sectioning with lots of irrigation
- ▣ Remove interseptal bone almost flush with cortical plates, again with lots of irrigation and light touch
- ▣ Thoroughly curette any granulation tissue and PDL

# Extraction of Mandibular 1<sup>st</sup> Molar with Immediate Implant

- ❑ Consider rinsing with hydrogen peroxide for decontamination, and rinse thoroughly with sterile water or saline.
- ❑ Measure socket depth on mesial and distal against both buccal and lingual cortical plates
- ❑ Most of the time you will not need to engage full depth of socket
- ❑ Determine ideal implant length with 2mm counter sink from lowest marginal ridge, most likely will be 9 mm or 11mm long

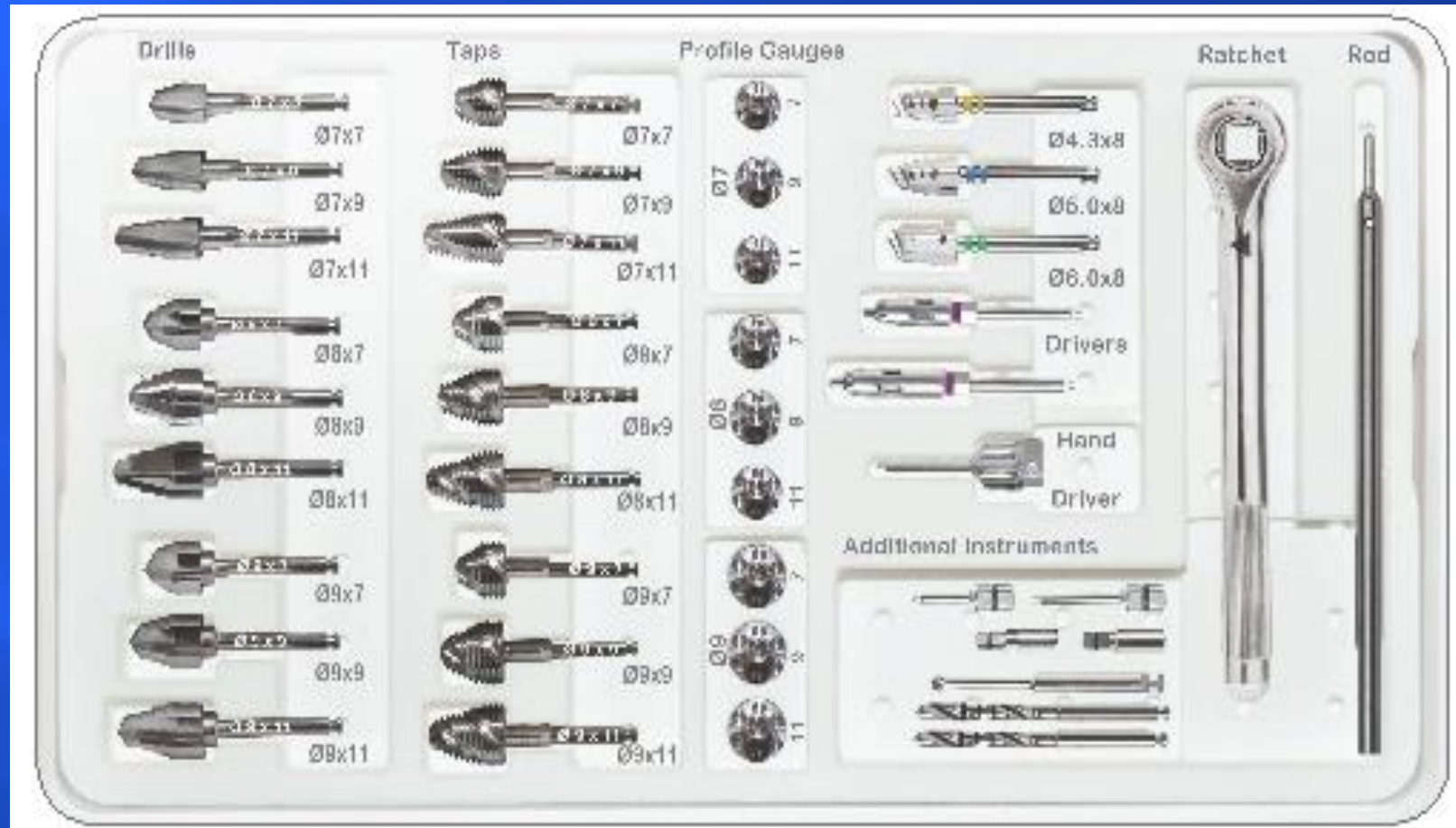
# Keystone Max implant

- ❑ Check fit with implant profile gauges, start with 7 mm wide by 9 mm long, verify that it goes in at the projected angle, rarely will bind with Mandibular first molars sites.
- ❑ Check gap on buccal and lingual, if loose, go to 8mm wide by 7 mm long and recheck buccal and lingual gap, this size most of the time will be tight and go about 1 mm above crest or flush with the crest.
- ❑ Run slowly the intermediate drill down to desired depth, most likely 11mm from lowest (most apical) portion of the crest.
- ❑ Slow speeds 150-450 rpm and hold the drill firmly, it will want to “chatter”

# Site preparation

- ▣ Use final drill down one size (i.e.-7mm wide for 8mm wide implant) for the implant selected, take to full depth
- ▣ Use tap drill, again one diameter size down from final implant diameter, (tap speed 50-75 rpm), being careful to make sure you have proper alignment
- ▣ Run tap down to desired depth
- ▣ Mount implant on fixture mount and at tap speed drive it down till torque limiter releases, most likely will be flush with crest
- ▣ Recheck alignment is still good, and place manual driver sleeve and wrench on fixture mount, and torque to final position usually 60+ Ncm
- ▣ May need to back off  $\frac{1}{4}$  turn for every  $\frac{1}{2}$  turn down till final seat

# MAX Dental Implant System



# MAX Dental Implant System

Ø8.0 x 9.0 mm



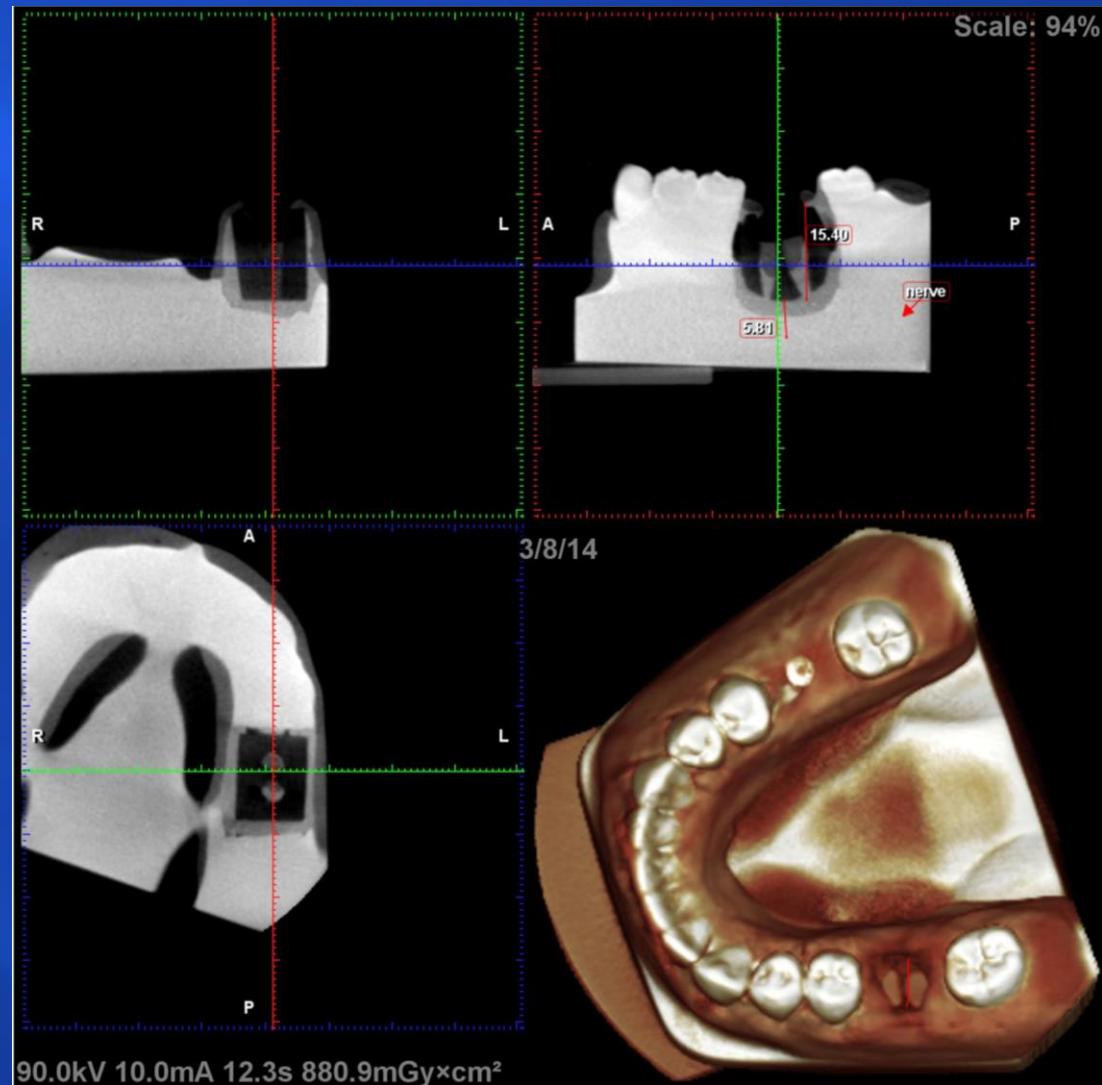
# Graft and impression

- ❑ Remove fixture mount and insert impression pin with some Neosporin cream on threads
- ❑ May want to place some graft at this time depending on whether there are “gaps” on the mesial and distal. Impression material can easily flow down these gaps and become very hard to remove, if not impossible
- ❑ Graft needs to be small particle size and slow resorbing such as Bio-Oss or Ingenious HA
- ❑ Pack graft tightly and make sure it is soaked with blood
- ❑ Fill only to top of implant at this time
- ❑ Take impression-VPS medium to light body, fast set

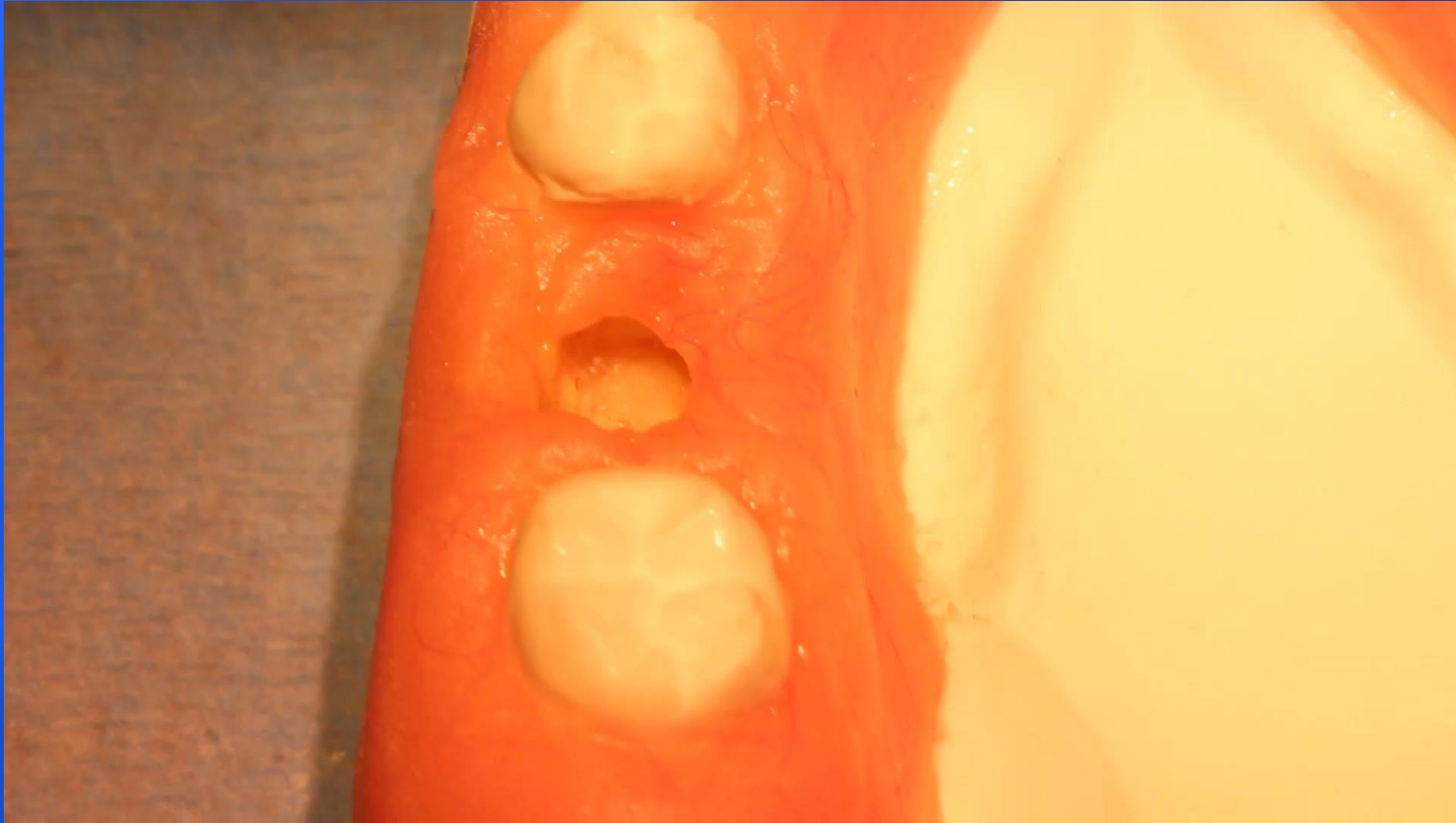# Healing abutment & addition grafting

- ❑ After impression verify that indexing flat is visible, and no major bubbles on contact areas of adjacent teeth
- ❑ Remove impression pin and insert healing abutment, add small amount of additional Neosporin cream and rinse
- ❑ Graft remaining socket till filled just short of gingival margin, all tissue must be supported
- ❑ Place gel foam “membrane” over grafted areas if bigger than 2mm wide
- ❑ Suture only if tissue is loose or papilla was released
- ❑ Seal with tissue glue
- ❑ Bite registration if needed

# Immediate Mandible Molar implant

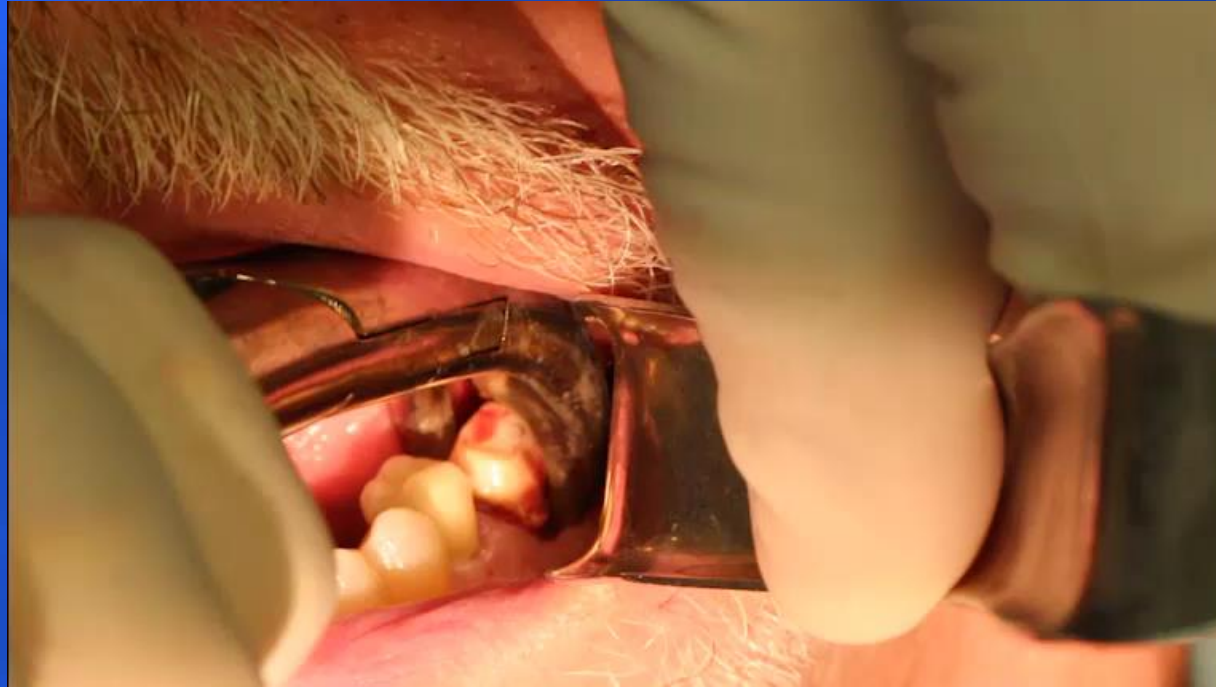


# Immediate Mandible Molar implant



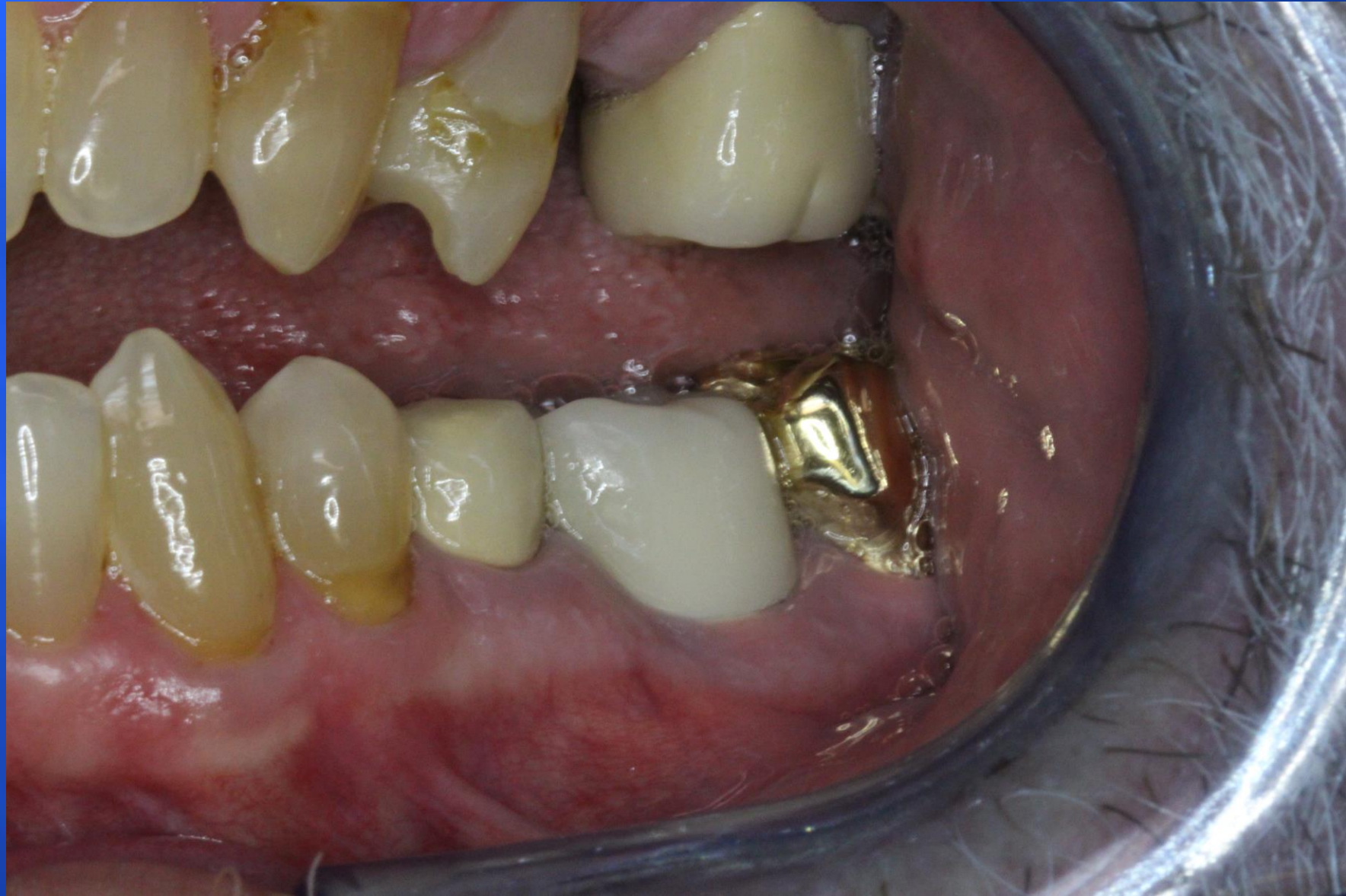(Video)

# Immediate Mandible Molar implant



(Video)

Post Op



# Immediate Maxillary 1<sup>st</sup> Molar Implant

## With Trans-Alveolar sinus lift/graft

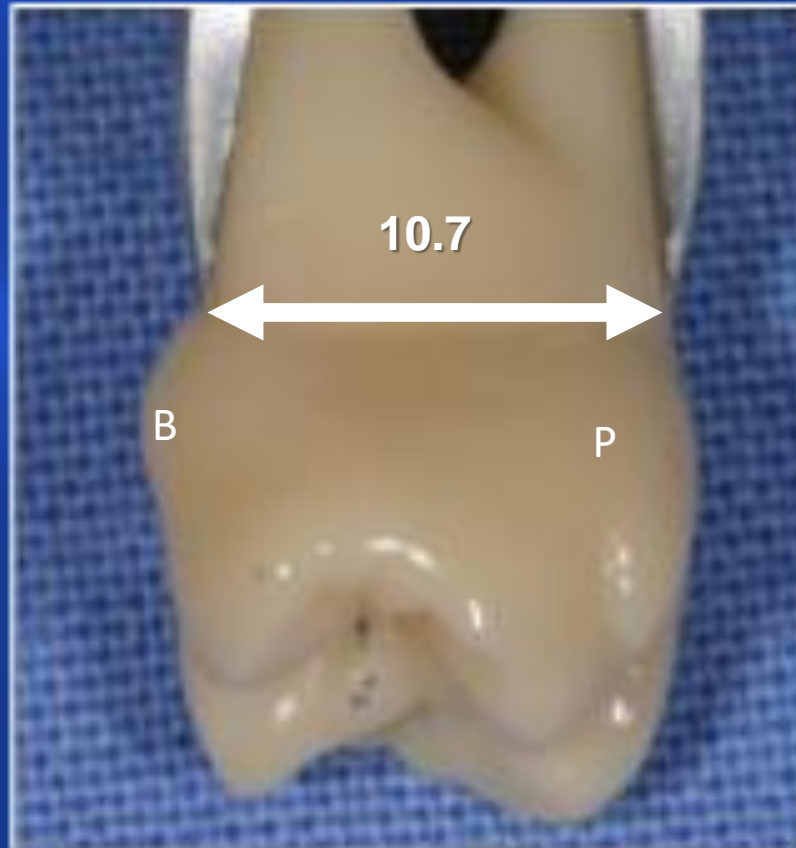
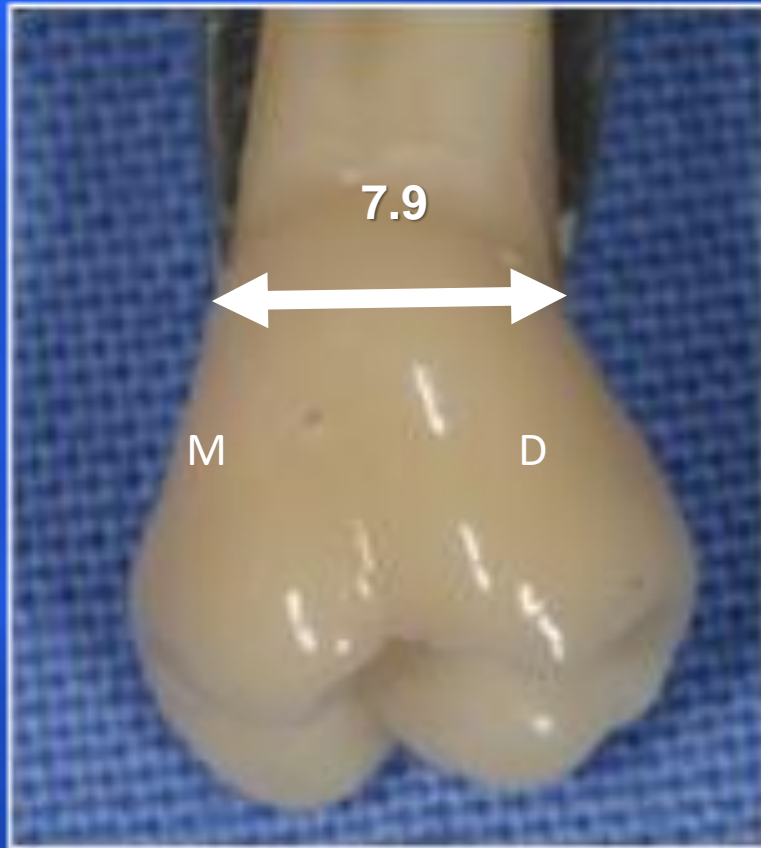
- ▣ Similar to immediate Mandibular molar ultra wide implant placement for indications and work up 3D Cone beam almost a must
- ▣ Careful, atraumatic tooth extraction-must section for removal and avoid buccal cortical plate
- ▣ Curette out all granulation tissue, and scrape PDL
- ▣ Consider rinsing with hydrogen peroxide for decontamination, and rinse thoroughly with sterile water or saline.

# Immediate Maxillary 1<sup>st</sup> Molar Implant

- ▣ Measure socket depth on MB, DB, and palatal roots against both buccal and lingual cortical plates
- ▣ Most of the time you will not need to engage full depth of socket
- ▣ Determine ideal implant length with 2mm counter sink from lowest marginal ridge, most likely will be 9 mm or 11mm long

# MAX Dental Implant System

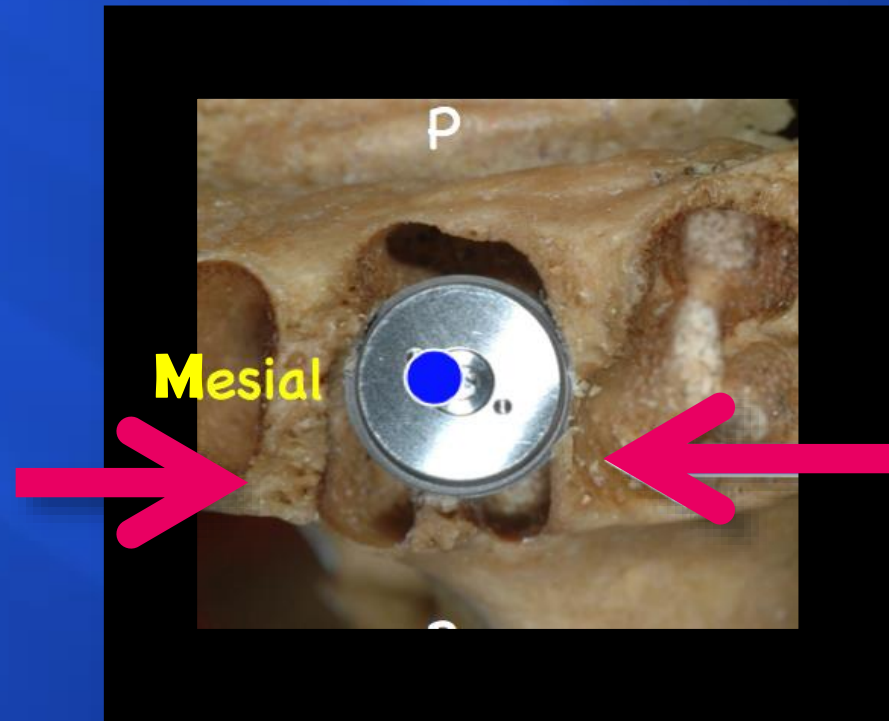
## Implant Sizing - Maxillary First Molar



# Tri-MAX Dental Implant System

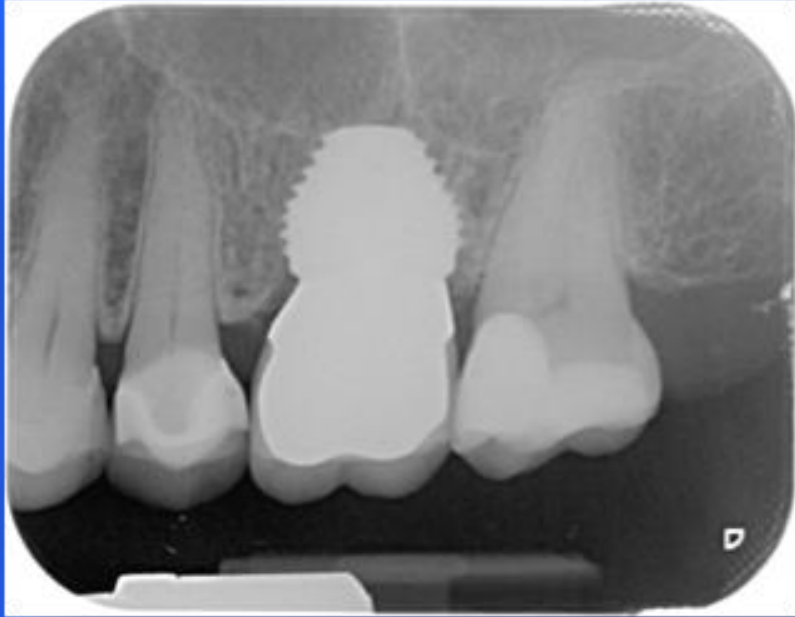
## Clinical Suggestions

- In the maxillary posterior it is recommended for placement to be **sub-crestal 2.0 mm, towards the mesial of the extraction socket, and 2.0 mm away from the buccal wall** for bone to cover threads.

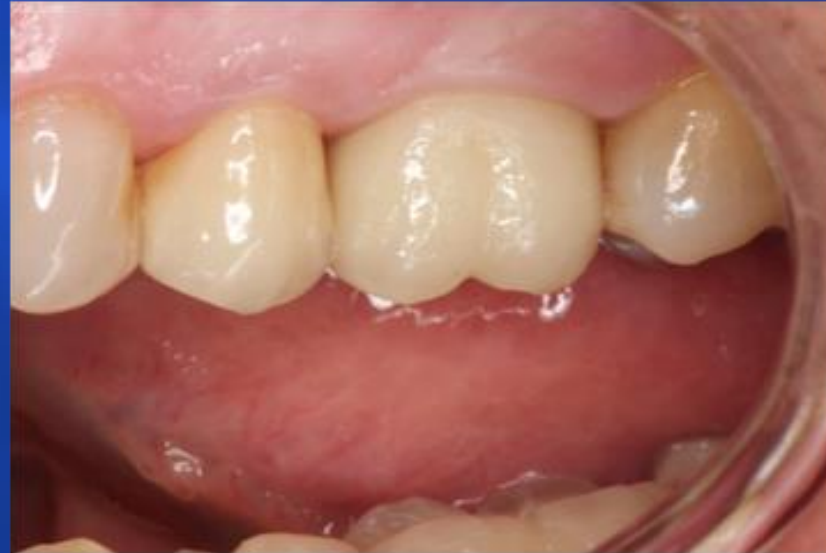

# Tri-MAX Dental Implant System

## Clinical Solutions

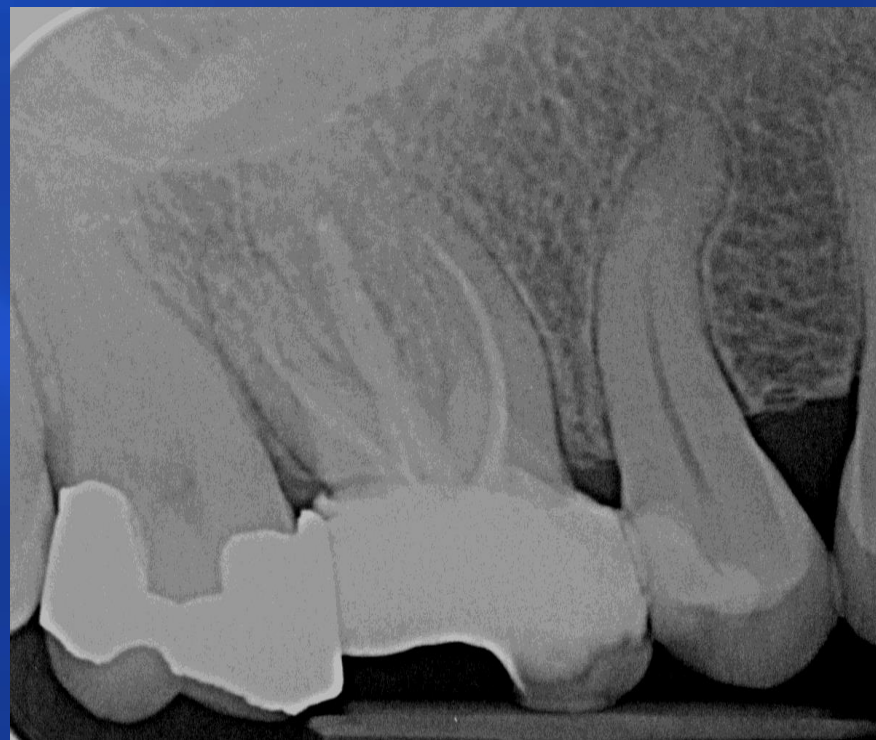
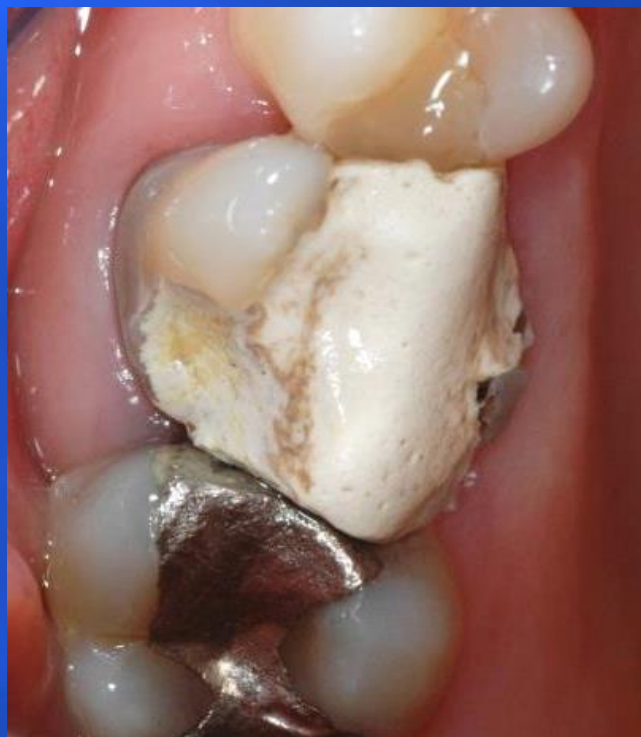
Maxilla



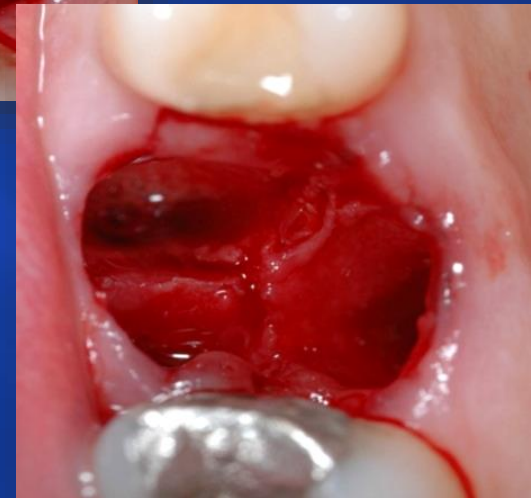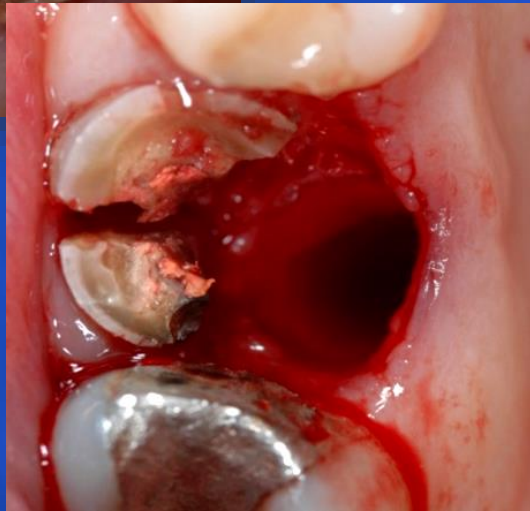
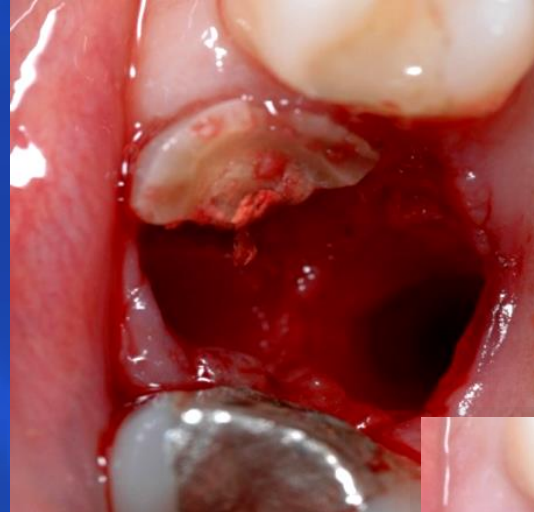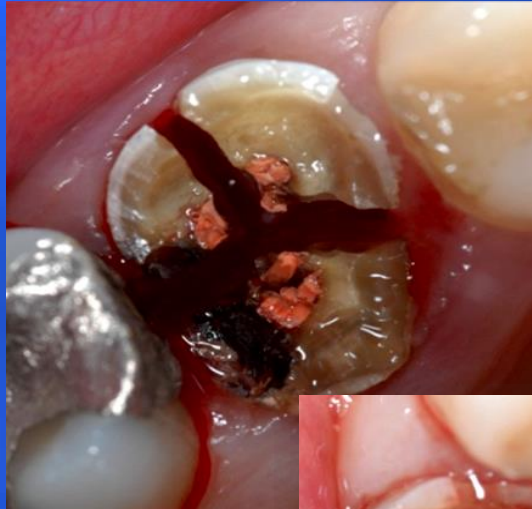Courtesy of Dr. A. Ackermann

# Clinical Case



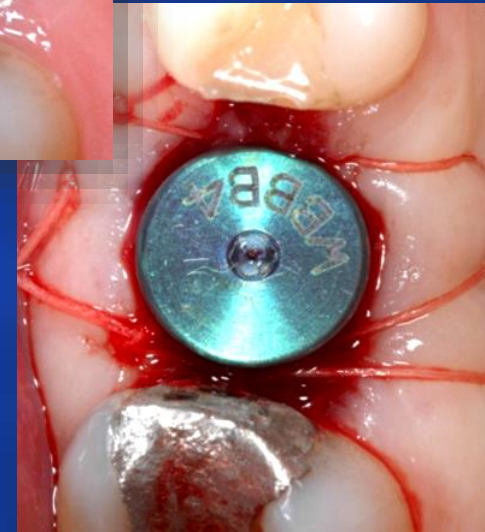
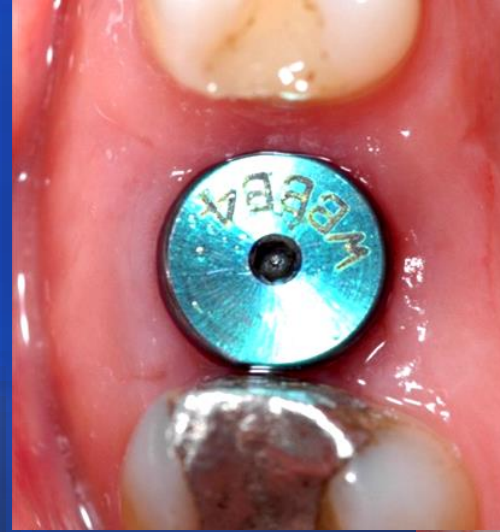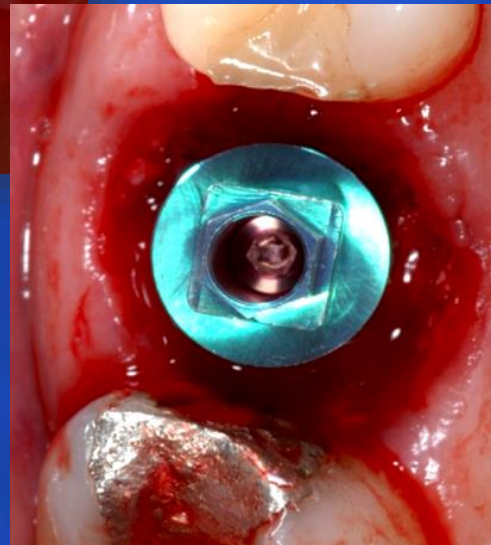
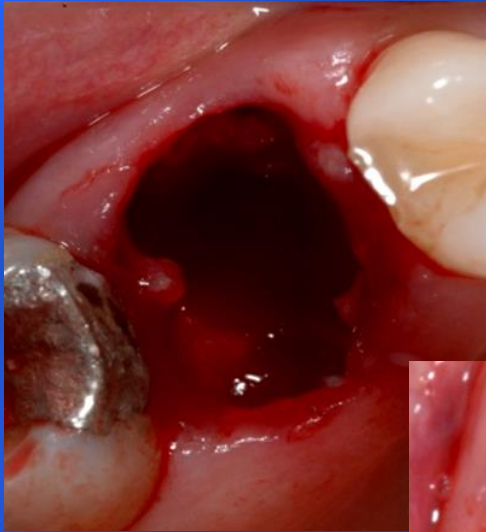
Courtesy of Dr. A. Hattingh, Perio

# Clinical Case



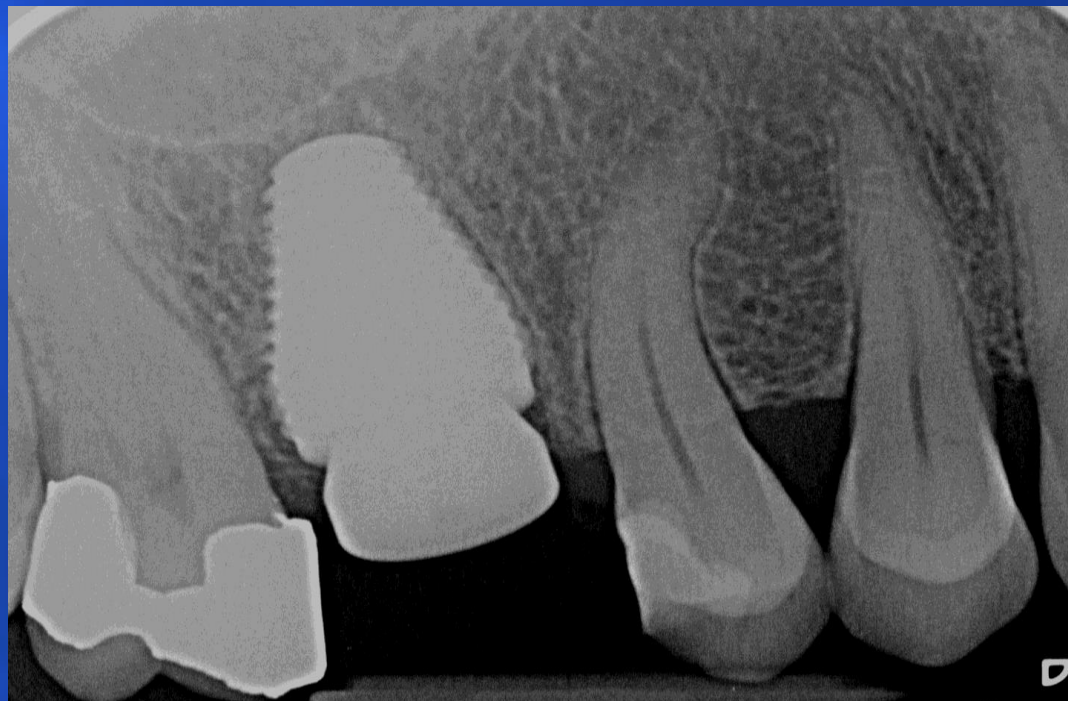Courtesy of Dr. A. Hattingh, Perio

# Clinical Case



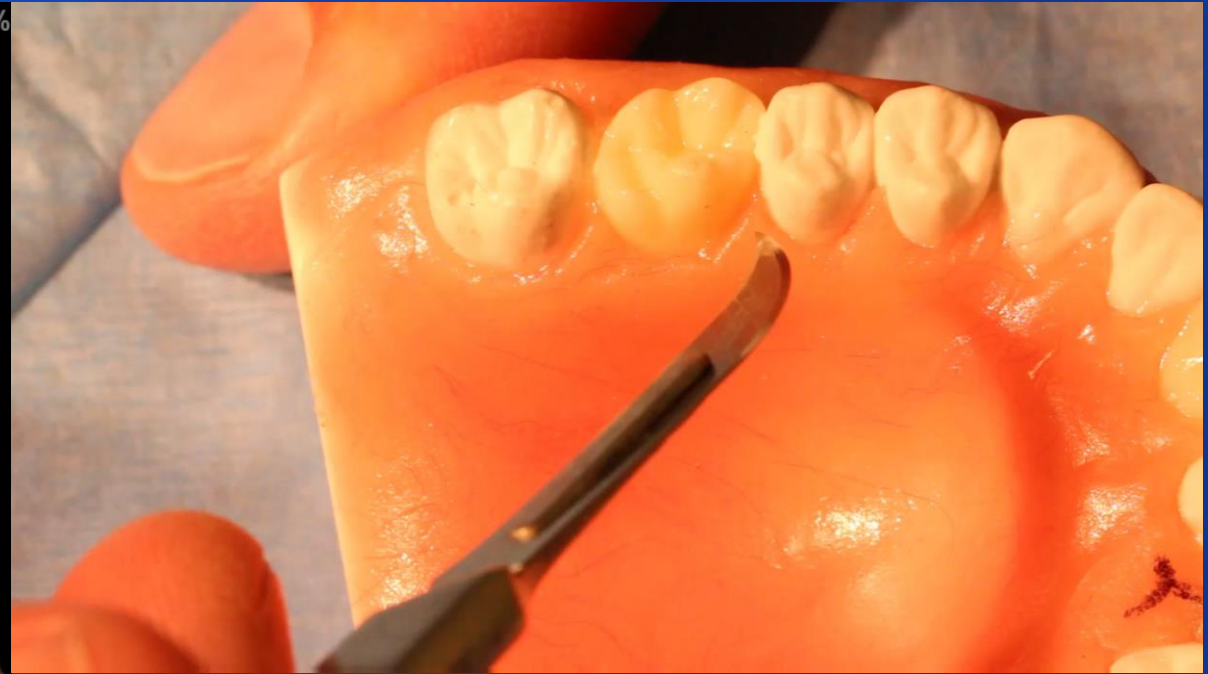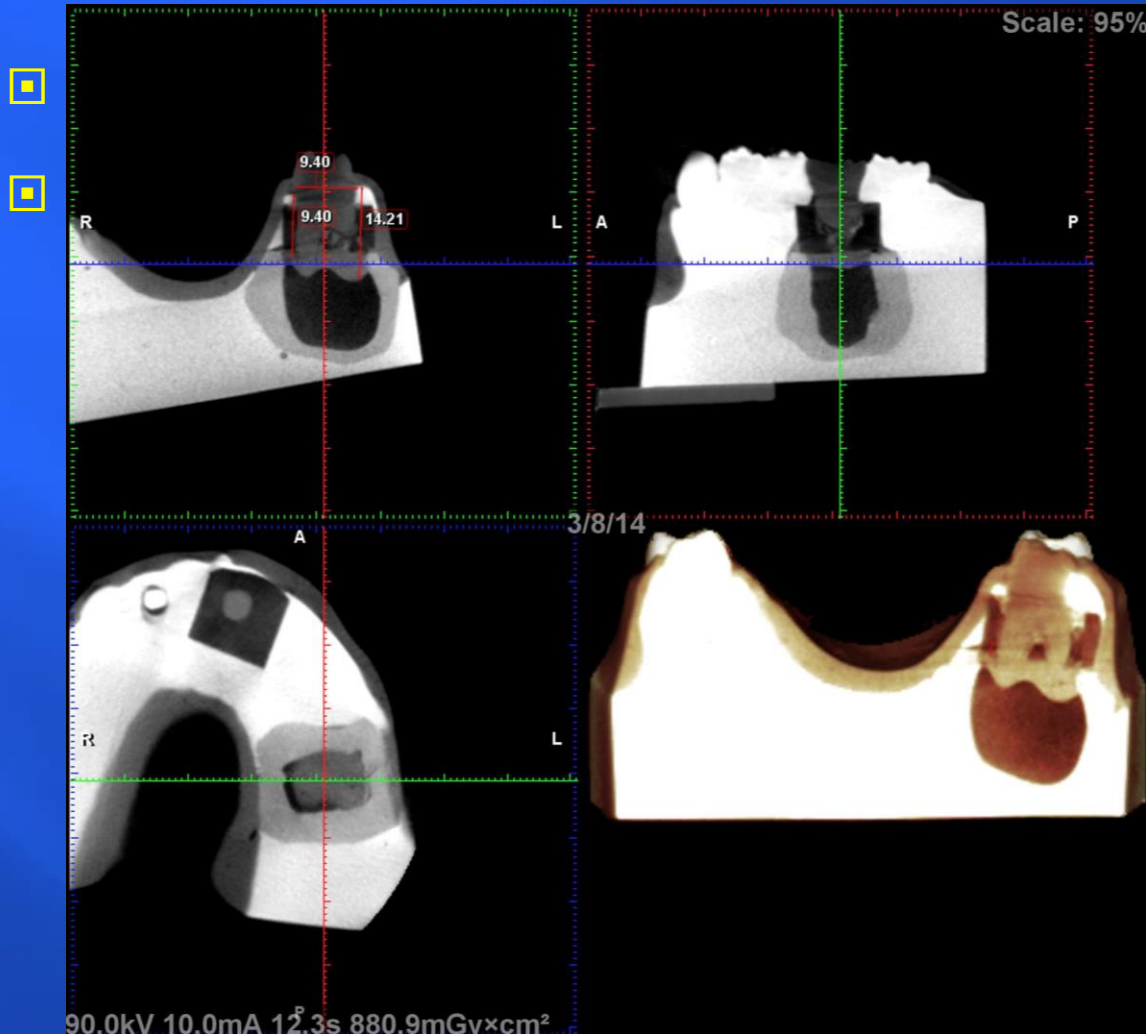
Courtesy of Dr. A. Hattingh, Perio

# Clinical Case



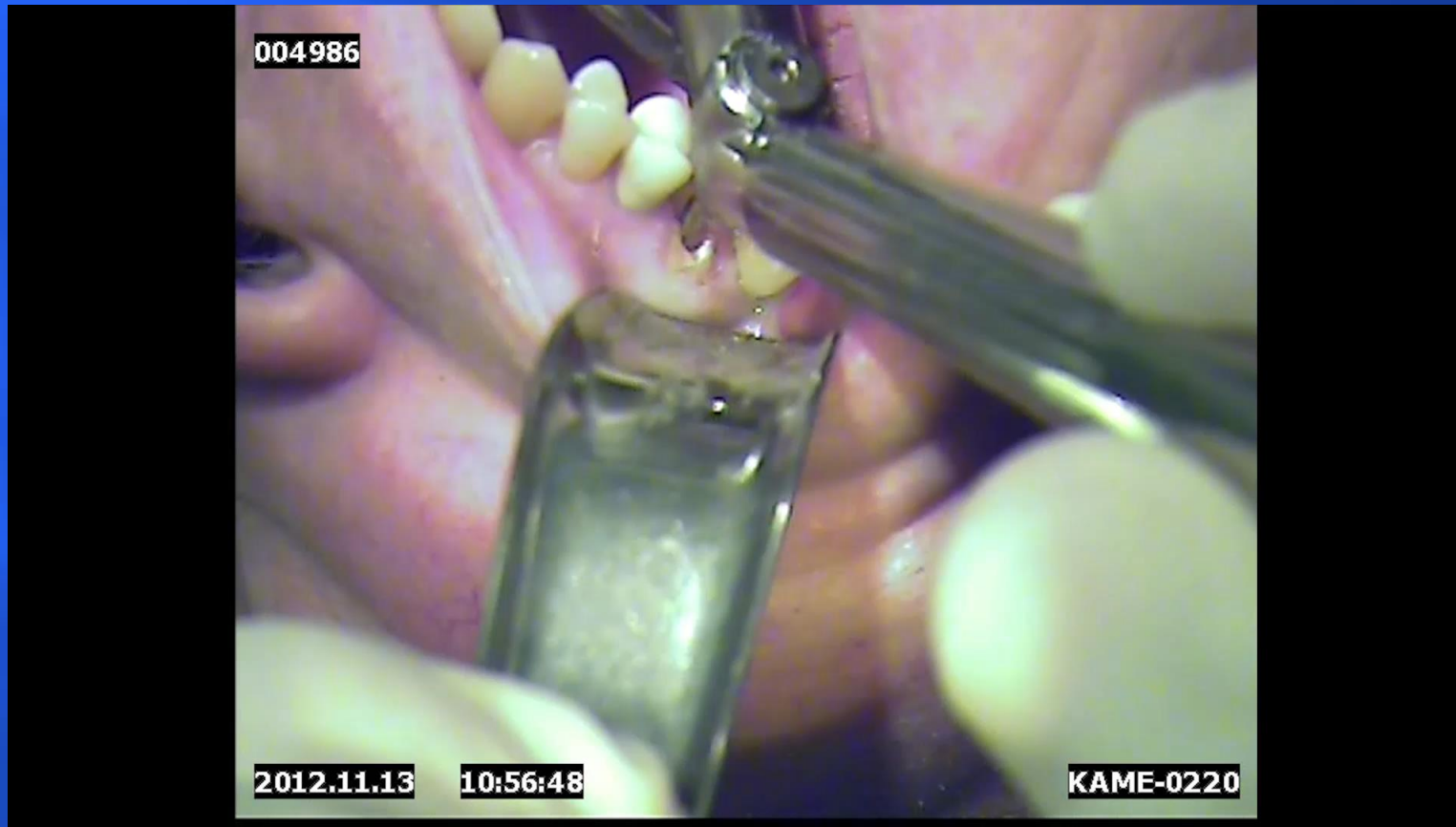Courtesy of Dr. A. Hattingh, Perio

# Immediate Maxillary 1<sup>st</sup> Molar Implant



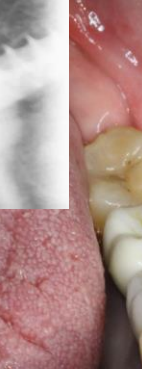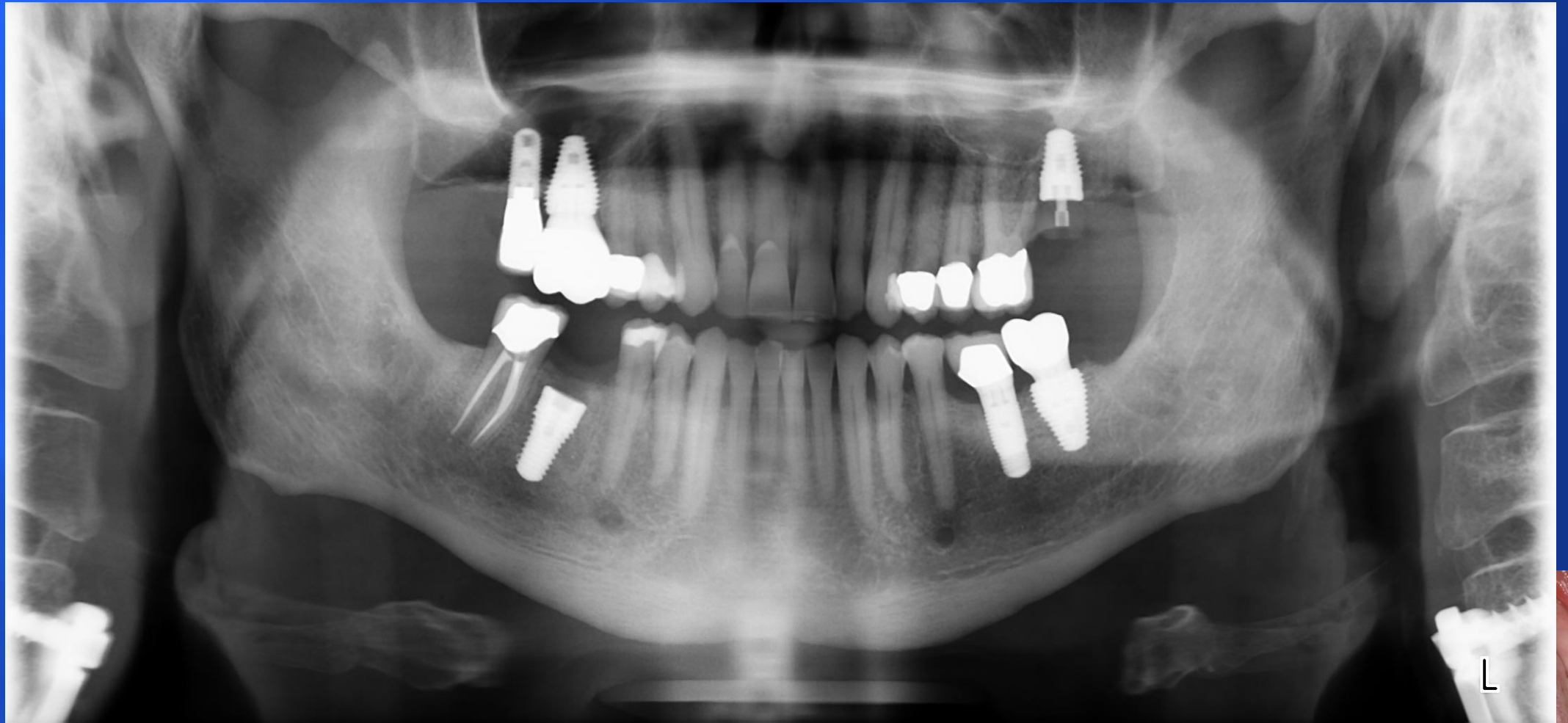(Video)

# Immediate Maxillary 1<sup>st</sup> Molar Implant



(Video)

# Post Op



# Tooth #8 (tooth in a day)

- ▣ Surgical removal of tooth #8 with horizontal root fracture
- ▣ Immediate implant placement with combination of drills and osteotomes
- ▣ Placement of socket graft
- ▣ Fabrication of immediate custom temporary abutment
- ▣ Fabrication and cementation of immediate temporary tooth

## Implants by System

InterActive™ System

Legacy™ System

Tri-lobe System

Swish™ System


Spectra-System®

Legacy™ 1

Legacy™ 2

Legacy™ 3

Legacy™ 4



Internal Hex Implants

# Tooth #8 (tooth in a day) Indications/Advantages

- ▣ Patient has only one surgery, compared to three
- ▣ Faster treatment time to final crown, 3 months versus 12 months
- ▣ Better support of and maintenance of hard and soft tissues of the esthetic zone

# Tooth #8 (tooth in a day)

## Indications

- ▣ Case selection: Ideal with no or minimal infection and intact buccal and lingual cortical plates at the crest
- ▣ No major hard or soft tissue defects
- ▣ Pre-operative x-rays; prefer 3D cone beam if possible but not mandatory
- ▣ Medical risk factors/Contraindications: diabetes, smoker, heavy Etoh use, poor oral hygiene, and immune system disorders

# Tooth #8 (tooth in a day) Sequence of Treatment

- ▣ Preoperative antibiotics-ideal 5 days of Keflex 500mg QID or Cleocin 150mg QID
- ▣ Preoperative Motrin 800mg or plain Tylenol 500mg
- ▣ Peridex or comparable preoperative mouth rinse
- ▣ Sedation orally or IV if warranted
- ▣ Impression for temporary if needed
- ▣ Opposing arch impression in alginate
- ▣ Preoperative photographs and shade selection
- ▣ Preoperative implant selection if 3DCB available, otherwise for centrals and canines a 4.5-5.0mm diameter by 13-16mm length implant. 3.5-4.0 diameter for lateral incisors

# Tooth #8 (tooth in a day)

## Sequence of treatment

- ❑ Local anesthesia-usually start with 3% Carbocaine plain, followed by 2% Lidocaine with Epi, and then 0.5% Marcaine with Epi (should be able to start immediately)
- ❑ Sulcular incision only with micro blade or #11 blade (try not to release papilla)
- ❑ Attempt removal with forceps. Recommend serrated or diamond coated. Keep slow steady rotational pressure-TAKE YOUR TIME
- ❑ If removing an existing crown to be used as a temporary, protect crown with gauze or a small piece of rubber dam, and very light “squeezing” force on the forceps. If successful hollow out crown with a coarse round diamond (#4) or football shape and lots of irrigation

# Tooth #8 (tooth in a day)

## Sequence of treatment

- ❑ Removal of remaining root: Use Woodson, microtomes, or piezoelectric ultrasonic (chisel tips)
- ❑ Thoroughly debride PDL and any peri-apical pathology
- ❑ Consider socket decontamination/irrigation with Plain hydrogen peroxide, sterile saline, and possibly Peridex
- ❑ Directly measure socket with periodontal probe to buccal and palatal crest of bone and soft tissue, have someone record this!
- ❑ Plan on counter sinking 2 mm below the lowest point of the bony crest, usually the buccal
- ❑ Check integrity of the cortical plates, especially the buccal

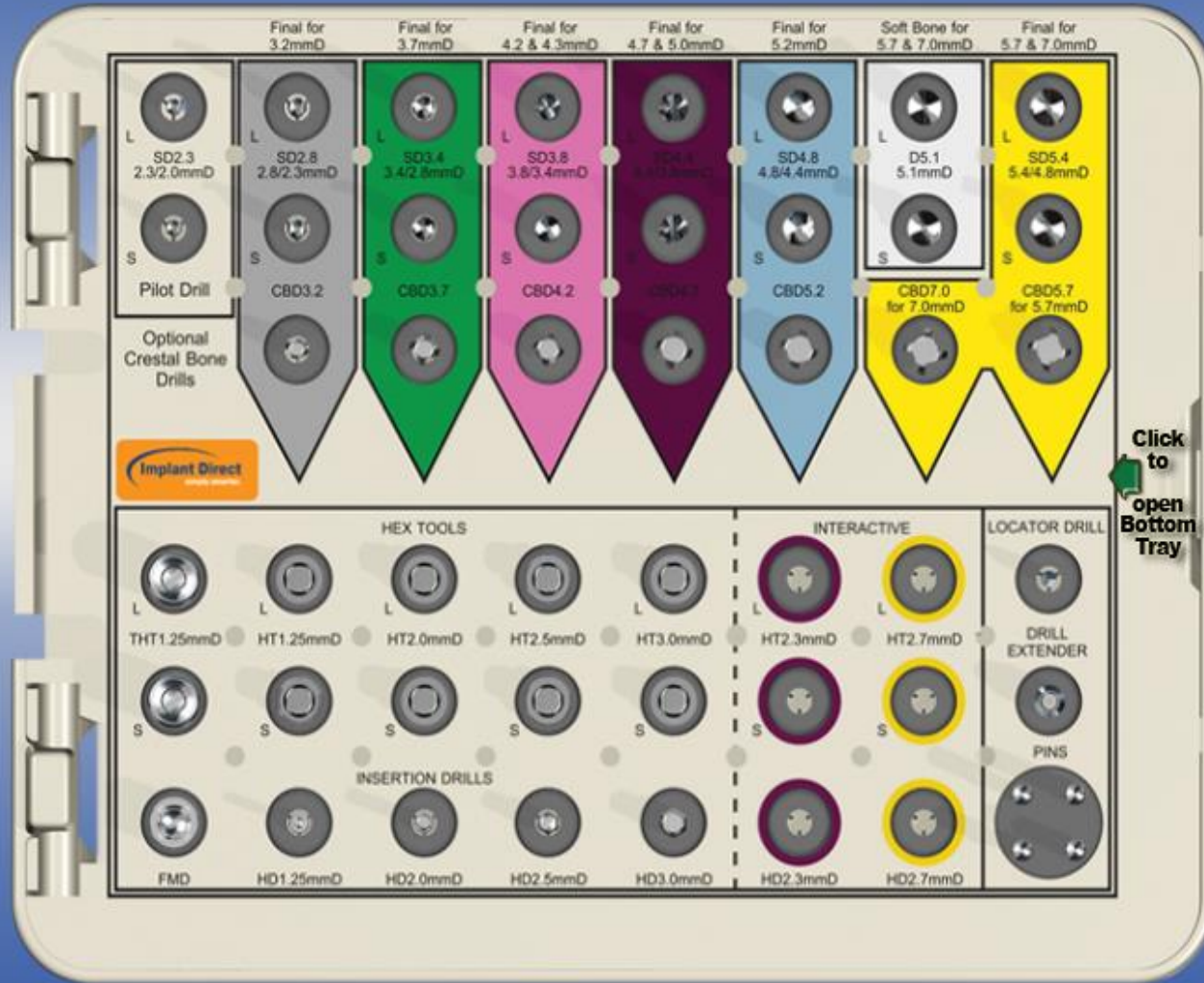
# Tooth #8 (tooth in a day)

## Sequence of treatment

- ❑ Check angulation of socket compared to adjacent roots, usually socket tapers toward the buccal
- ❑ Start preparation with the Lindeman drill with extender attached and angle most of the time towards the palate, once engaged straighten the drill to the ideal angle and drill in a few millimeters (3-5mm) and remeasure
- ❑ Continue with Lindeman drill to just sort of final depth, for a 16 mm implant + 2mm countersink + soft tissue thickness(1.5-2mm)
- ❑ Insert small diameter osteotome and “push” or mallet to final depth, then continue drilling with pilot drill 2.3 mm

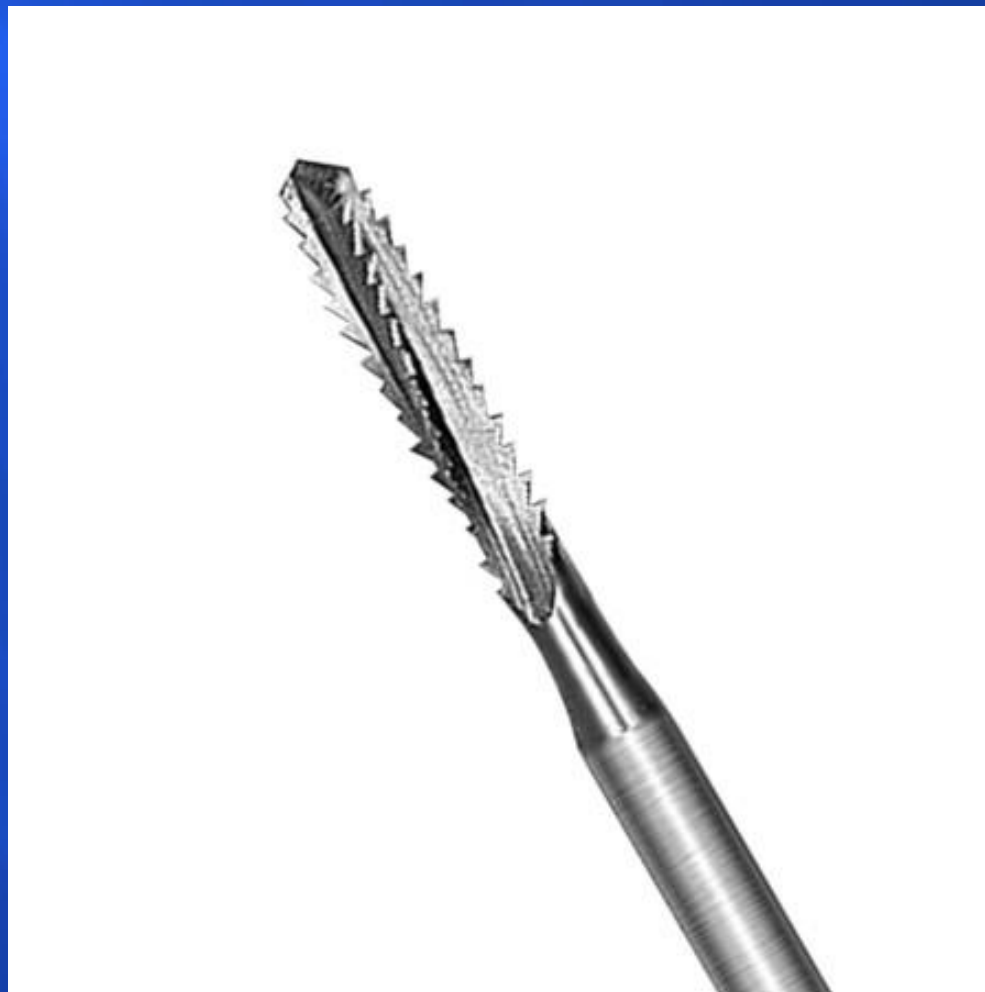

# Complete Surgical Tray



Surgical Tray Contents		Price
Description		
<b>ST</b>	<b>Surgical Tray (Empty)</b>	<b>\$250.00</b>
SD2.3	2.3/2.0mmD Step Drill-Long	\$60.00
SD2.3S	2.3/2.0mmD Step Drill-Short	\$60.00
SD2.8	2.8/2.3mmD Step Drill-Long	\$60.00
SD2.8S	2.8/2.3mmD Step Drill-Short	\$60.00
CBD3.2	3.2mmD Cortical Drill	\$60.00
SD3.4	3.4/2.8mmD Step Drill-Long	\$60.00
SD3.4S	3.4/2.8mmD Step Drill-Short	\$60.00
CBD3.7	3.7mmD Cortical Drill	\$60.00
SD3.8	3.8/3.4mmD Step Drill-Long	\$60.00
SD3.8S	3.8/3.4mmD Step Drill-Short	\$60.00
CBD4.2	4.2mmD Cortical Drill	\$60.00
SD4.4	4.4/3.8mmD Step Drill-Long	\$60.00
SD4.4S	4.4/3.8mmD Step Drill-Short	\$60.00
CBD4.7	4.7mmD Cortical Drill	\$60.00
SD4.8	4.8/4.4mmD Step Drill-Long	\$60.00
SD4.8S	4.8/4.4mmD Step Drill-Short	\$60.00
CBD5.2	5.2mmD Cortical Drill	\$60.00
D5.1	5.1mmD Straight Drill-Long	\$60.00
D5.1S	5.1mmD Straight Drill-Short	\$60.00
SD5.4	5.4/4.8mmD Step Drill-Long	\$60.00
SD5.4S	5.4/4.8mmD Step Drill-Short	\$60.00
CBD5.7	5.7mmD Cortical Drill	\$60.00
<b>Hex Tools</b>		
THT1.25	1.25mmD Tapered Hex Tool-Long	\$40.00
THT1.25S	1.25mmD Tapered Hex Tool-Short	\$40.00
HT1.25	1.25mmD Straight Hex Tool-Long	\$40.00
HT1.25S	1.25mmD Straight Hex Tool-Short	\$40.00
HT2.0	2.0mmD Hex Tool-Long	\$40.00
HT2.0S	2.0mmD Hex Tool-Short	\$40.00
HT2.5	2.5mmD Hex Tool-Long	\$40.00
HT2.5S	2.5mmD Hex Tool-Short	\$40.00
HT3.0	3.0mmD Hex Tool-Long	\$40.00
HT3.0S	3.0mmD Hex Tool-Short	\$40.00
HD1.25	1.25mmD Hex Drill	\$40.00
HD2.0	2.0mmD Hex Drill	\$40.00
HD2.5	2.5mmD Hex Drill	\$40.00
HD3.0	3.0mmD Hex Drill	\$40.00
<b>Ancillary Instrumentation</b>		
FMD	Fixture Mount Drill	\$80.00
LDRILL	Locator Drill	\$30.00
DE	Drill Extender	\$40.00
R	Ratchet	\$125.00
PAR (x4)	Paralleling Tool 2.8/2.3	\$60.00
SSH2.5	2.5mmD Stainless Steel Handle	\$100.00
		<b>\$2,565.00</b>

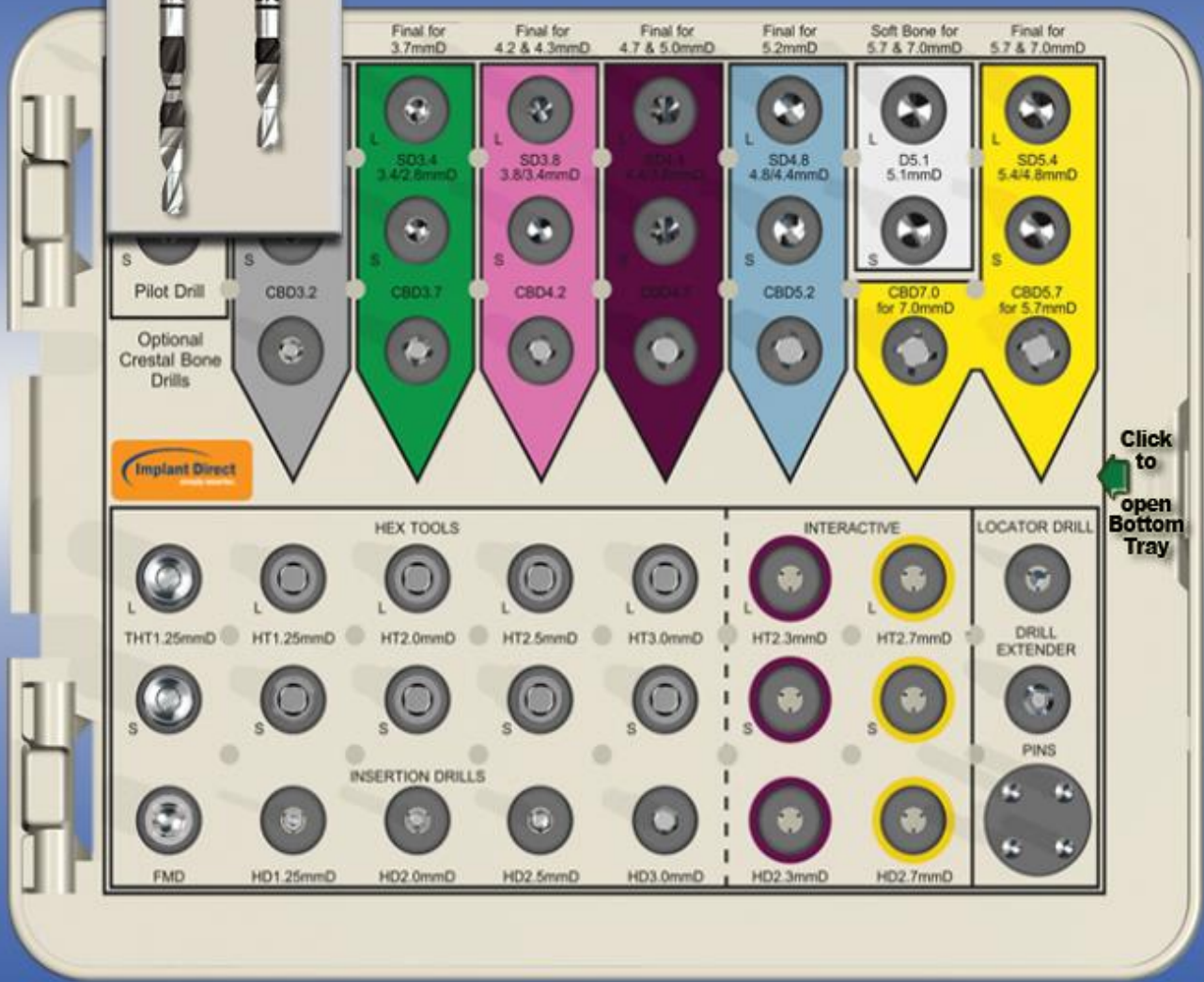
# Lindemann bur





SD2.3 SD2.3S

# Complete Surgical Tray



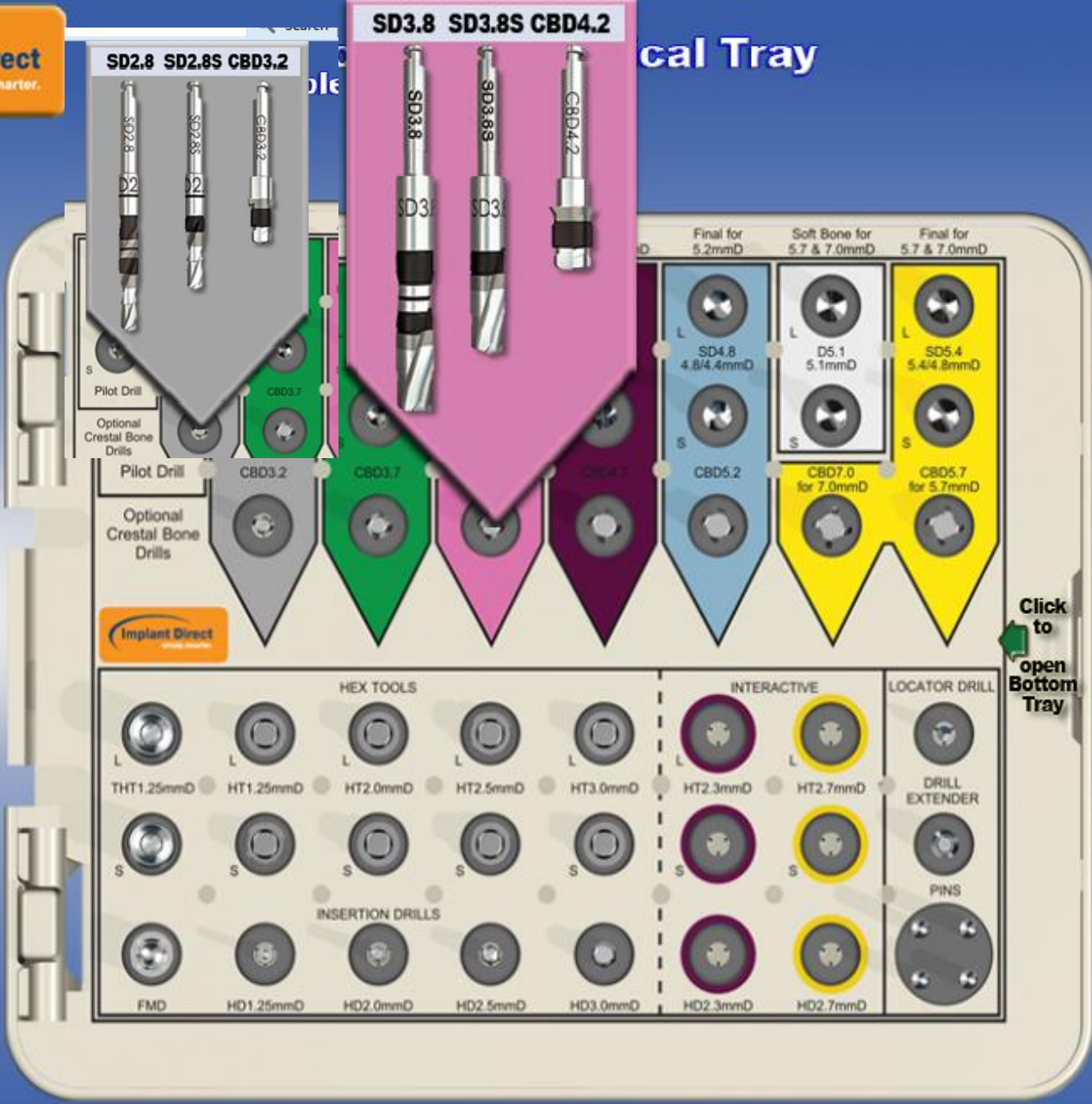
Click to  
open  
Bottom  
Tray

Surgical Tray Contents		Price
Description		
ST	Surgical Tray (Empty)	\$250.00
SD2.3	2.3/2.0mmD Step Drill-Long	\$60.00
SD2.3S	2.3/2.0mmD Step Drill-Short	\$60.00
SD2.8	2.8/2.3mmD Step Drill-Long	\$60.00
SD2.8S	2.8/2.3mmD Step Drill-Short	\$60.00
CBD3.2	3.2mmD Cortical Drill	\$60.00
SD3.4	3.4/2.8mmD Step Drill-Long	\$60.00
SD3.4S	3.4/2.8mmD Step Drill-Short	\$60.00
CBD3.7	3.7mmD Cortical Drill	\$60.00
SD3.8	3.8/3.4mmD Step Drill-Long	\$60.00
SD3.8S	3.8/3.4mmD Step Drill-Short	\$60.00
CBD4.2	4.2mmD Cortical Drill	\$60.00
SD4.4	4.4/3.8mmD Step Drill-Long	\$60.00
SD4.4S	4.4/3.8mmD Step Drill-Short	\$60.00
CBD4.7	4.7mmD Cortical Drill	\$60.00
SD4.8	4.8/4.4mmD Step Drill-Long	\$60.00
SD4.8S	4.8/4.4mmD Step Drill-Short	\$60.00
CBD5.2	5.2mmD Cortical Drill	\$60.00
D5.1	5.1mmD Straight Drill-Long	\$60.00
D5.1S	5.1mmD Straight Drill-Short	\$60.00
SD5.4	5.4/4.8mmD Step Drill-Long	\$60.00
SD5.4S	5.4/4.8mmD Step Drill-Short	\$60.00
CBD5.7	5.7mmD Cortical Drill	\$60.00
<b>Hex Tools</b>		
THT1.25	1.25mmD Tapered Hex Tool-Long	\$40.00
THT1.25S	1.25mmD Tapered Hex Tool-Short	\$40.00
HT1.25	1.25mmD Straight Hex Tool-Long	\$40.00
HT1.25S	1.25mmD Straight Hex Tool-Short	\$40.00
HT2.0	2.0mmD Hex Tool-Long	\$40.00
HT2.0S	2.0mmD Hex Tool-Short	\$40.00
HT2.5	2.5mmD Hex Tool-Long	\$40.00
HT2.5S	2.5mmD Hex Tool-Short	\$40.00
HT3.0	3.0mmD Hex Tool-Long	\$40.00
HT3.0S	3.0mmD Hex Tool-Short	\$40.00
HD1.25	1.25mmD Hex Drill	\$40.00
HD2.0	2.0mmD Hex Drill	\$40.00
HD2.5	2.5mmD Hex Drill	\$40.00
HD3.0	3.0mmD Hex Drill	\$40.00
<b>Ancillary Instrumentation</b>		
FMD	Fixture Mount Drill	\$80.00
LDRILL	Locator Drill	\$30.00
DE	Drill Extender	\$40.00
R	Ratchet	\$125.00
PAR (x4)	Paralleling Tool 2.8/2.3	\$60.00
SSH2.5	2.5mmD Stainless Steel Handle	\$100.00
		<b>\$2,565.00</b>

# Tooth #8 (tooth in a day)

## Sequence of treatment

- ▣ Start using irrigation at this point and drill next sequence up alternating a larger osteotome inserted to compress the bone laterally.
- ▣ Drill slow usually around 300-450 RPM
- ▣ Carefully check alignment each time you insert a drill or osteotome
- ▣ Implant angle in most cases is not going to fall on incisal edge
- ▣ Drill/compress “one sequence” short of final drill size I.E.- 3.8 mm diameter for a 4.7 drill or 2.8 mm for a 3.7 mm implant



# Surgical Tray

## Surgical Tray Contents

Description	Price
ST Surgical Tray (Empty)	\$250.00
SD2.3 2.3/2.0mmD Step Drill-Long	\$60.00
SD2.3S 2.3/2.0mmD Step Drill-Short	\$60.00
SD2.8 2.8/2.3mmD Step Drill-Long	\$60.00
SD2.8S 2.8/2.3mmD Step Drill-Short	\$60.00
CBD3.2 3.2mmD Cortical Drill	\$60.00
SD3.4 3.4/2.8mmD Step Drill-Long	\$60.00
SD3.4S 3.4/2.8mmD Step Drill-Short	\$60.00
CBD3.7 3.7mmD Cortical Drill	\$60.00
SD3.8 3.8/3.4mmD Step Drill-Long	\$60.00
SD3.8S 3.8/3.4mmD Step Drill-Short	\$60.00
CBD4.2 4.2mmD Cortical Drill	\$60.00
SD4.4 4.4/3.8mmD Step Drill-Long	\$60.00
SD4.4S 4.4/3.8mmD Step Drill-Short	\$60.00
CBD4.7 4.7mmD Cortical Drill	\$60.00
SD4.8 4.8/4.4mmD Step Drill-Long	\$60.00
SD4.8S 4.8/4.4mmD Step Drill-Short	\$60.00
CBD5.2 5.2mmD Cortical Drill	\$60.00
D5.1 5.1mmD Straight Drill-Long	\$60.00
D5.1S 5.1mmD Straight Drill-Short	\$60.00
SD5.4 5.4/4.8mmD Step Drill-Long	\$60.00
SD5.4S 5.4/4.8mmD Step Drill-Short	\$60.00
CBD5.7 5.7mmD Cortical Drill	\$60.00
<b>Hex Tools</b>	
THT1.25 1.25mmD Tapered Hex Tool-Long	\$40.00
THT1.25S 1.25mmD Tapered Hex Tool-Short	\$40.00
HT1.25 1.25mmD Straight Hex Tool-Long	\$40.00
HT1.25S 1.25mmD Straight Hex Tool-Short	\$40.00
HT2.0 2.0mmD Hex Tool-Long	\$40.00
HT2.0S 2.0mmD Hex Tool-Short	\$40.00
HT2.5 2.5mmD Hex Tool-Long	\$40.00
HT2.5S 2.5mmD Hex Tool-Short	\$40.00
HT3.0 3.0mmD Hex Tool-Long	\$40.00
HT3.0S 3.0mmD Hex Tool-Short	\$40.00
HD1.25 1.25mmD Hex Drill	\$40.00
HD2.0 2.0mmD Hex Drill	\$40.00
HD2.5 2.5mmD Hex Drill	\$40.00
HD3.0 3.0mmD Hex Drill	\$40.00
<b>Ancillary Instrumentation</b>	
FMD Fixture Mount Drill	\$80.00
LDRILL Locator Drill	\$30.00
DE Drill Extender	\$40.00
R Ratchet	\$125.00
PAR (x4) Paralleling Tool 2.8/2.3	\$60.00
SSH2.5 2.5mmD Stainless Steel Handle	\$100.00

**\$2,565.00**

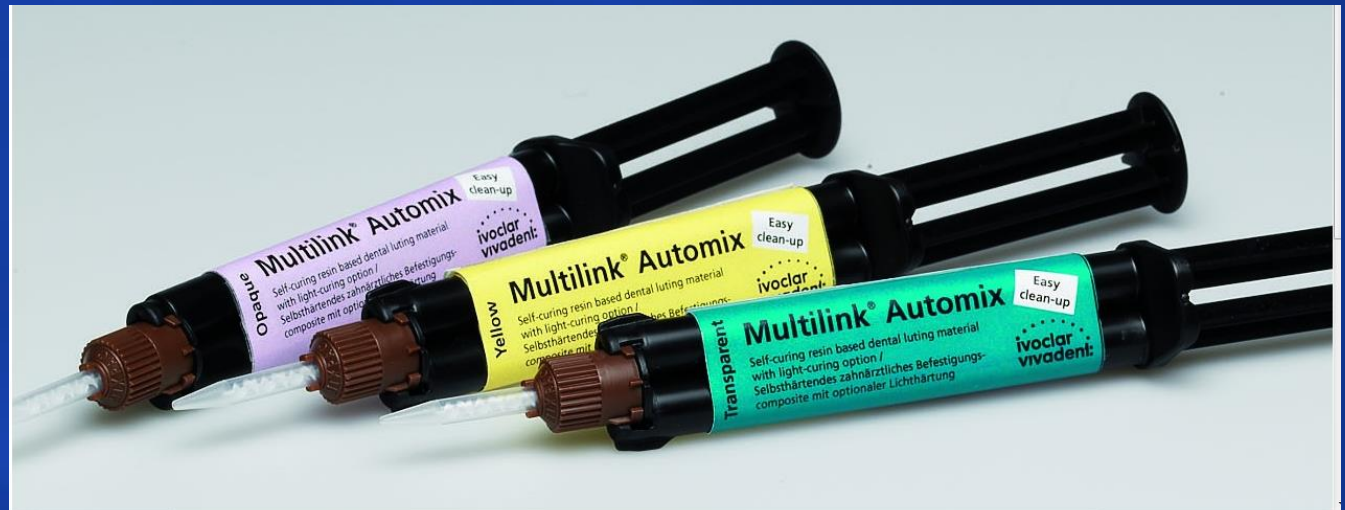# Tooth #8 (tooth in a day)

## Sequence of treatment

- ❑ Remove implant and either mount on fixture mount or manual hand driver and insert implant into site holding tightly against palatal wall and ensure implant is engaging the prepared angle; it will want to push away towards the buccal
- ❑ If implant starts to “float” towards the buccal, back the implant off and reinsert, same procedure if it also binds with high torque on seating, remember “metal shop” one turn in, 1/4 turn back!
- ❑ Notice hex flat position on implant and remove impression pin, drive implant down to final position with hex tool/ratchet, and try to finish hex parallel to buccal plate

# Tooth #8 (tooth in a day) Sequence of treatment

- ❑ Prepare temporary plastic (PEEK) abutment by coating with Tenure(optional), blow dry and apply a thin coating of multilink automix down to margin and light cure; select a shade to use
- ❑ Try abutment onto implant keeping groove to buccal for orientation and estimate amount of additional multilink needed to fully support soft tissue at least 1-2 mm above the crest
- ❑ It is critically important that the abutment fully seats passively!!!!

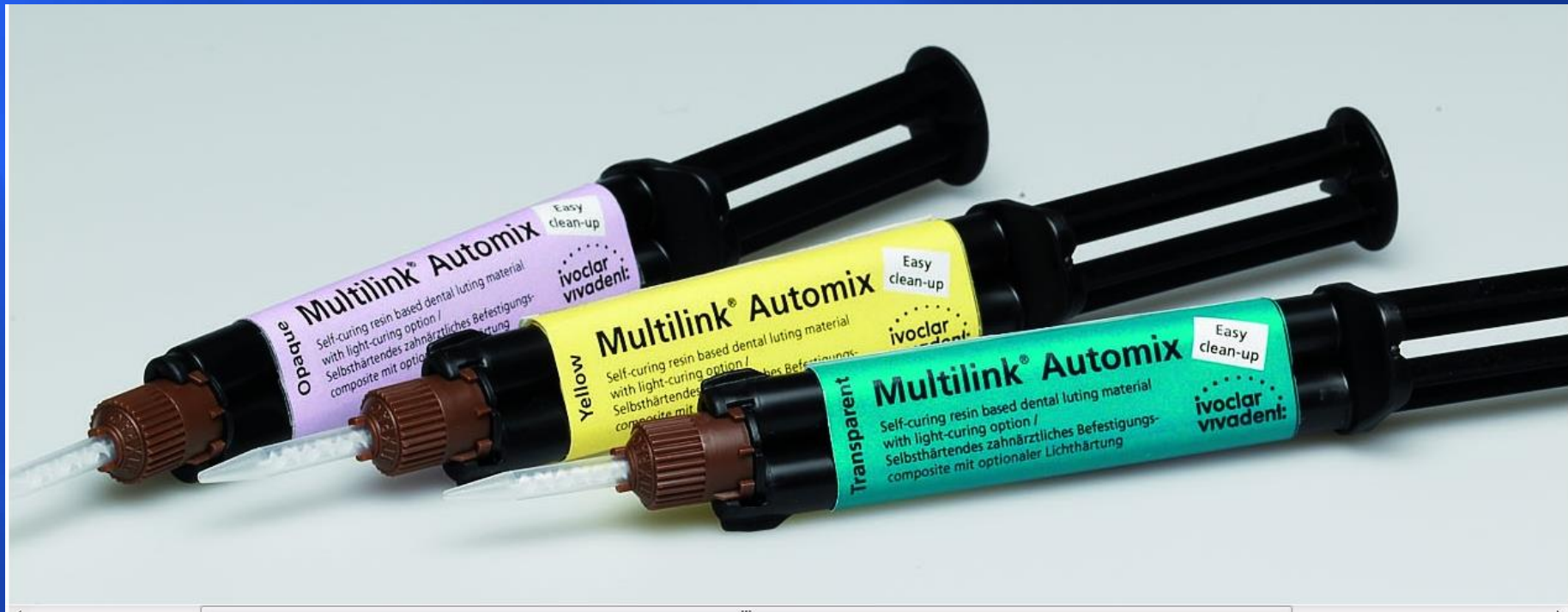

Select a shade if available  
Yellow is about B2 shade



### Shades

Transparent, yellow, white (NEW) and opaque



# Tooth #8 (tooth in a day)

## Sequence of treatment

- ▣ Place cover cap on lightly with some Neosporin cream
- ▣ Reconstitute granular graft material with sterile water or left over local anesthesia (Marcaine) and pack down around implant, may need to use flat narrow instrument such as the Woodson to effecting get the material down the neck of the implant, pack firmly
- ▣ Replace cover cap with a straight impression pin; check to make sure the indexing flat is visible and fully seated; check for graft
- ▣ Fill impression pin access hole with soft rope wax and take impression in material of choice, VPS. Check impression for indexing flat and adjacent contacts

# Tooth #8 (tooth in a day)

## Sequence of treatment

- ▣ Remove impression pin carefully, clean any graft off the top of the implant, (Q-tip) and insert custom temporary abutment with additional small amount of Neosporin cream, and torque till solid, around 15-20 Ncm<sup>2</sup>
- ▣ Ideal prep abutment with coarse tapered diamond burr and copious irrigation flush with gingival crest
- ▣ Size plastic polycarbonate temporary crown to fit over prepped abutment or old crown if salvageable. Extend margins to gingival crest.
- ▣ Check occlusion with crown in position

70-2004-091-7  
001-0

**3M ESPE**  
Polycarbonate Crowns

- ⓓ Polycarbonatkronen
- ⓕ Couronne polycarbonate
- Ⓛ Corone provvisorie in policarbonato
- ⓔ Couronne polycarbonate
- Ⓟ Corona de Policarbonato
- ⓃL Polycarbonaat kroon
- ⓖR Πολυκαρβονούχες στεφάνες
- Ⓢ Polykarbonat kronor
- ⓕN Polykarbonaattikruunut
- ⓓK Polykarbonat Kroner
- Ⓝ Polykarbonat-krone

CONTENTS

180



C-180



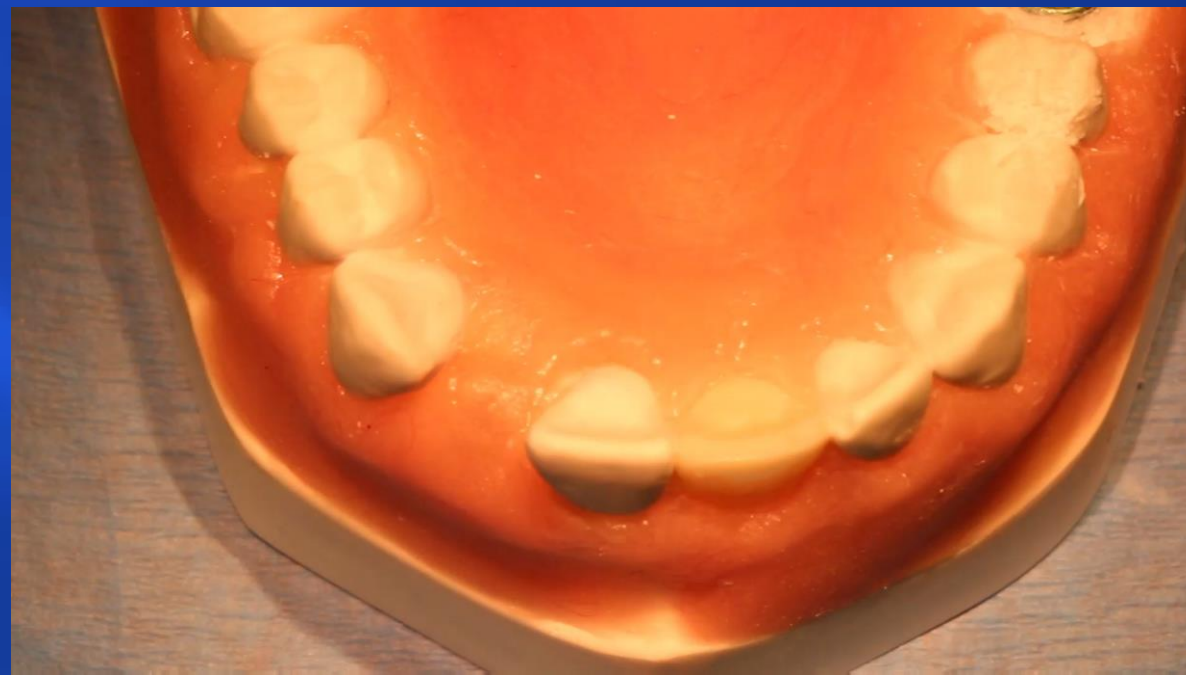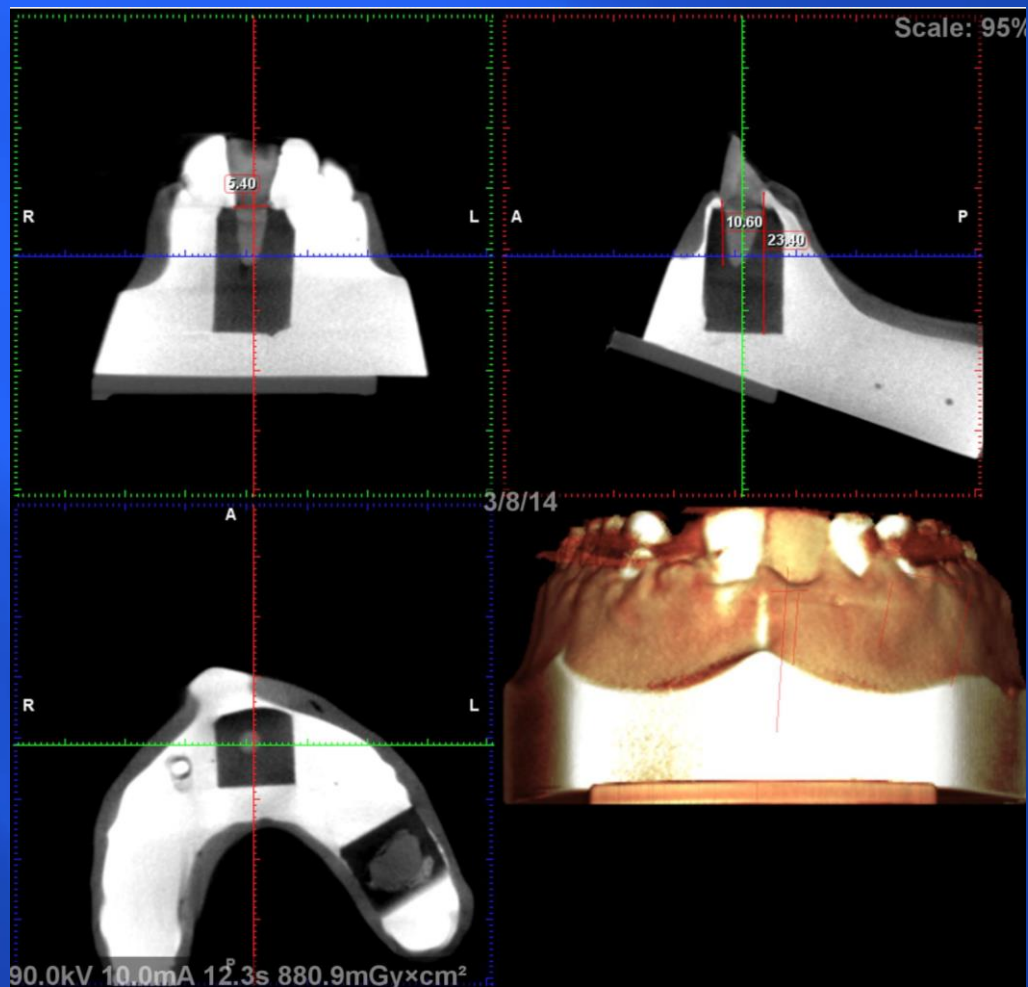
3M ESPE  
Polycarbonate Crowns - Adult Anterior

# Tooth #8 (tooth in a day)

## Sequence of treatment

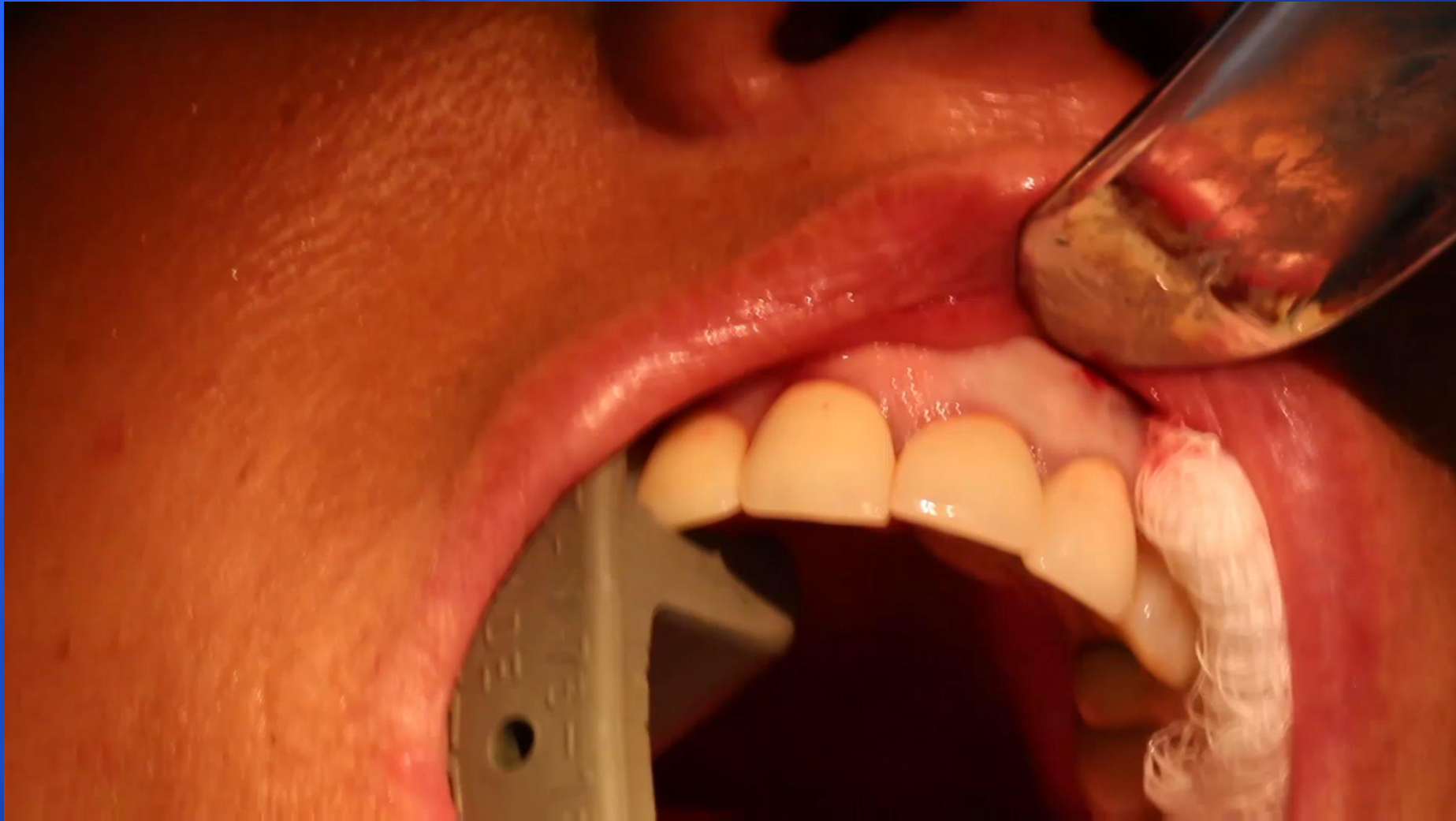- ❑ Fill access hole in temporary plastic abutment with soft rope wax
- ❑ Paint inside of temporary crown with Jet acrylic monomer and blow dry
- ❑ Thoroughly rinse abutment and dry
- ❑ Cement crown with Multilink automix dual cure resin cement
- ❑ Position carefully, clean excess cement, and light cure into position with patient in centric relation occlusion
- ❑ After fully cured, trim any excess cement with a high speed ultra fine flame diamond
- ❑ Check occlusion and adjust to being just out of contact
- ❑ Inject Decadron 4mg into vestibule for swelling/pain

# Tooth #8 (tooth in a day) Sequence of treatment



(Video)

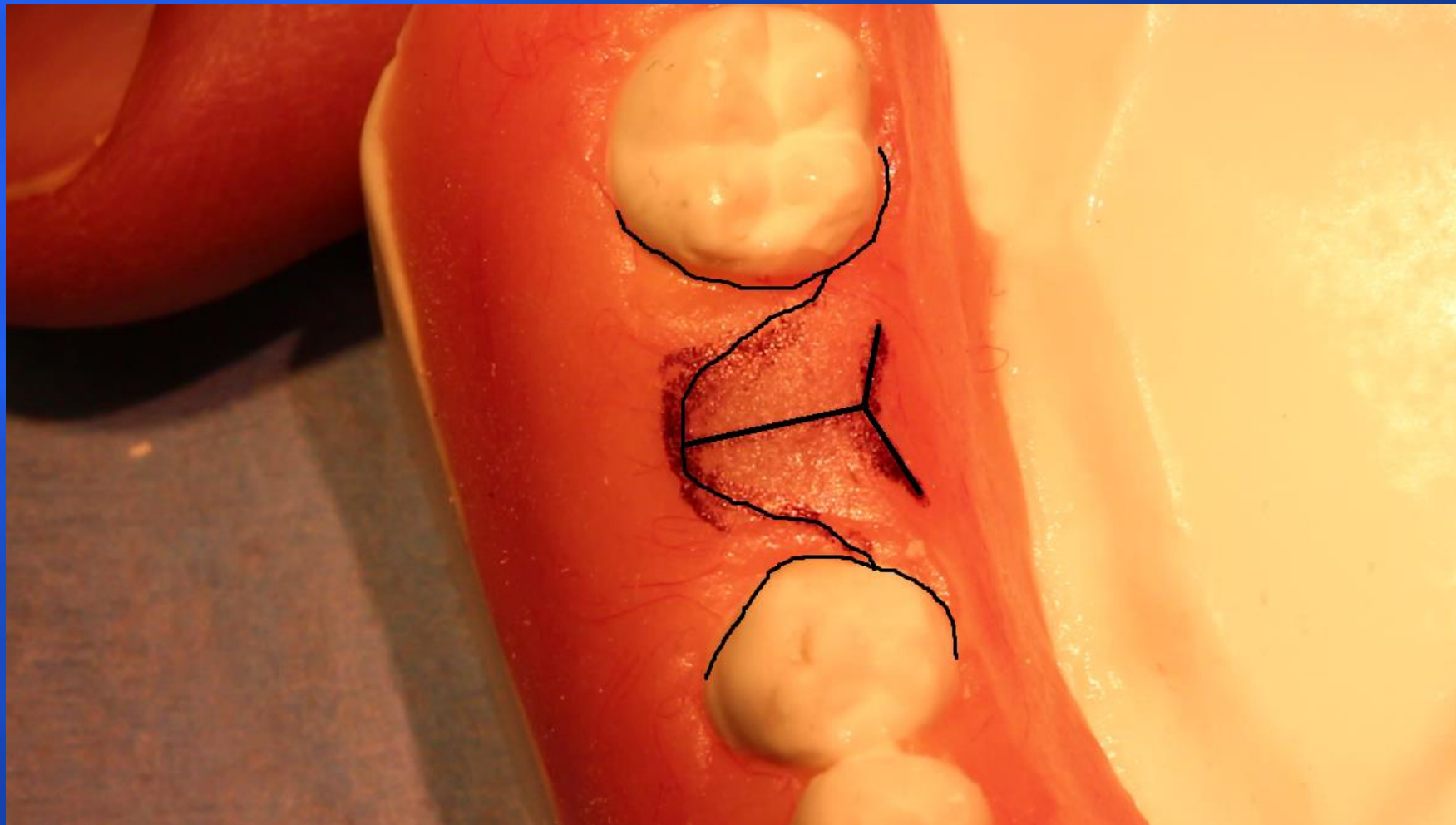
# Tooth #8 (tooth in a day) Sequence of treatment



# Surgical 2<sup>nd</sup> stage uncovering of implant #30 with Z-Plasty reconstruction of the papilla & insert of custom abutment

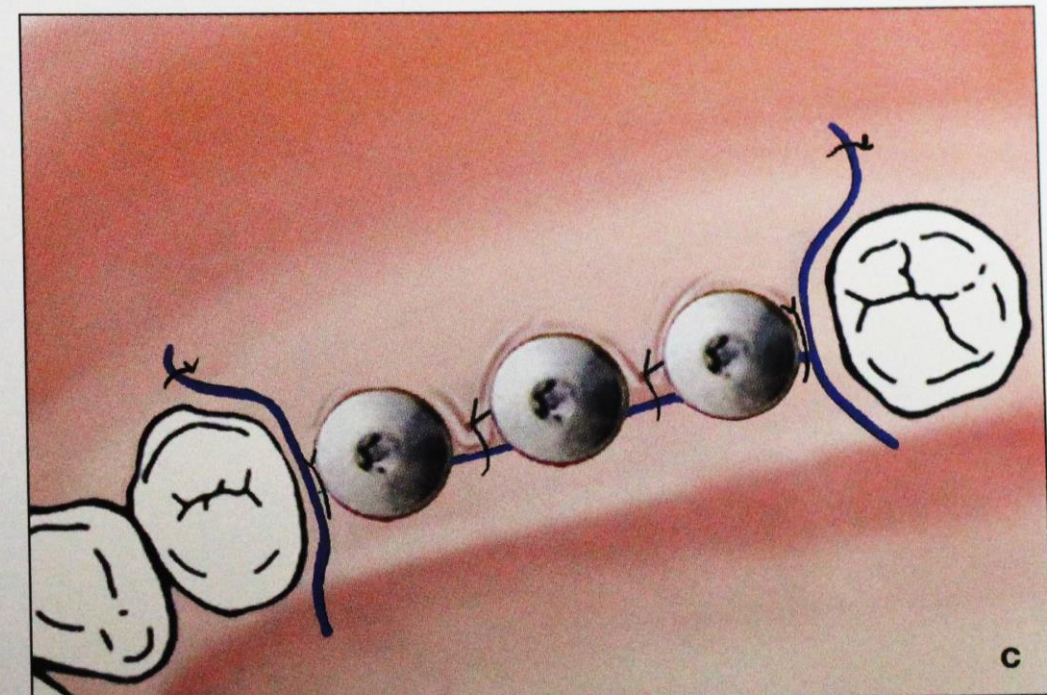
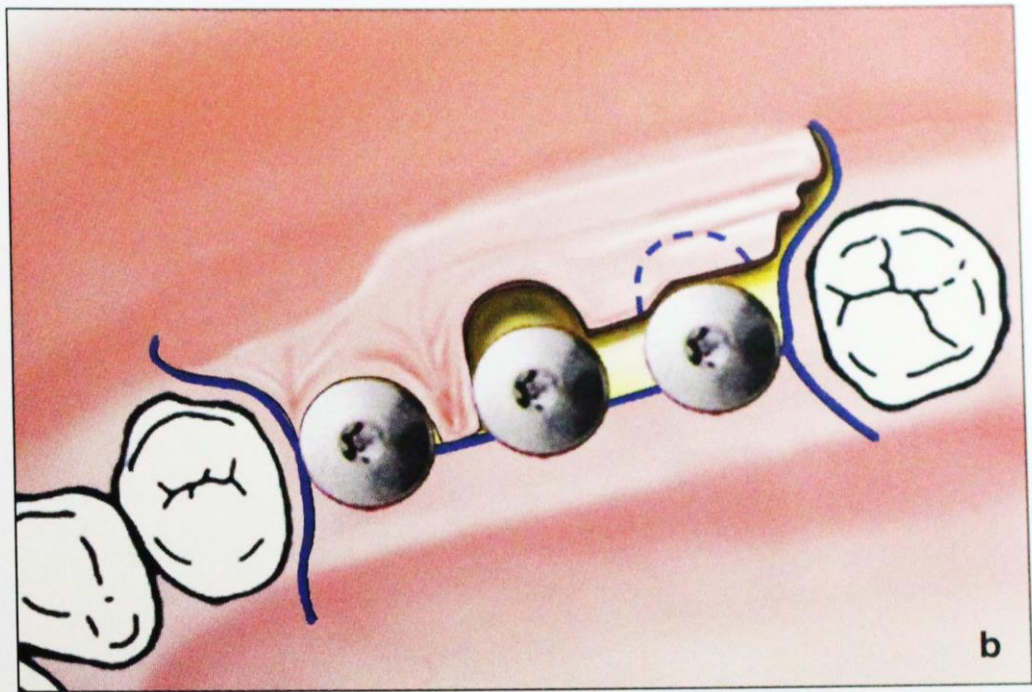
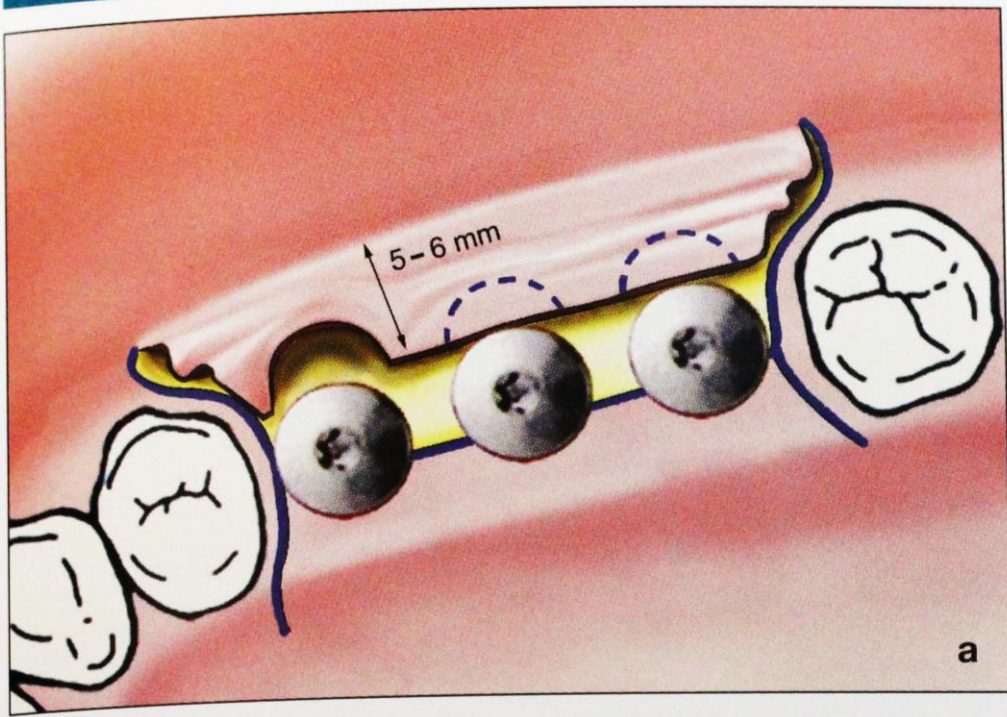
- ▣ Outline procedure on implant model or paper if an impression was not taken at the time of implant placement
- ▣ Assess the exact location of the Muco-gingival junction and how much attached mucosa is present, best if > 4mm
- ▣ Assess if additional graft or contour is needed on buccal

Surgical 2<sup>nd</sup> stage uncovering of  
implant #30 with Z-Plasty  
reconstruction of the papilla & insert  
of custom abutment

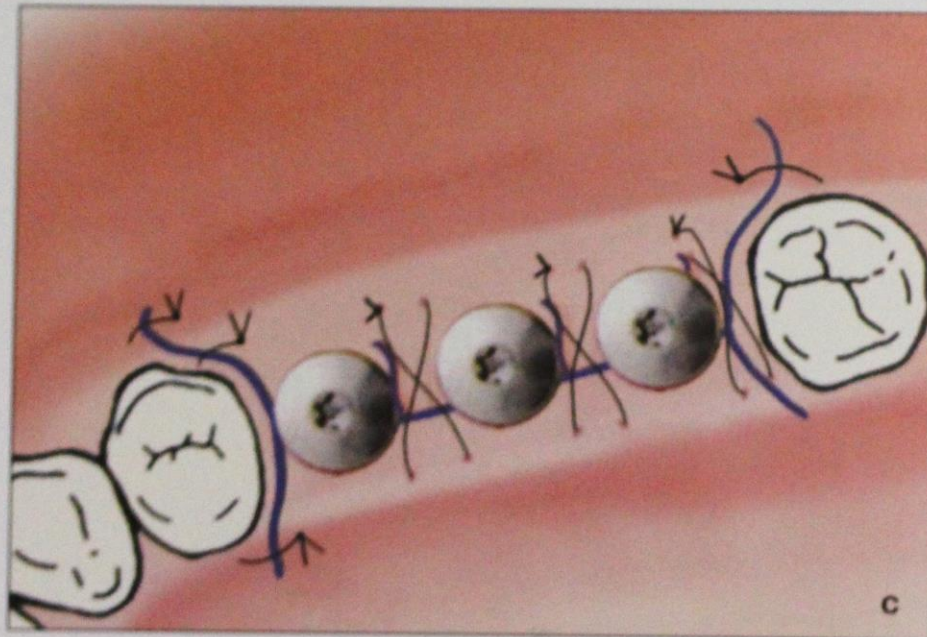
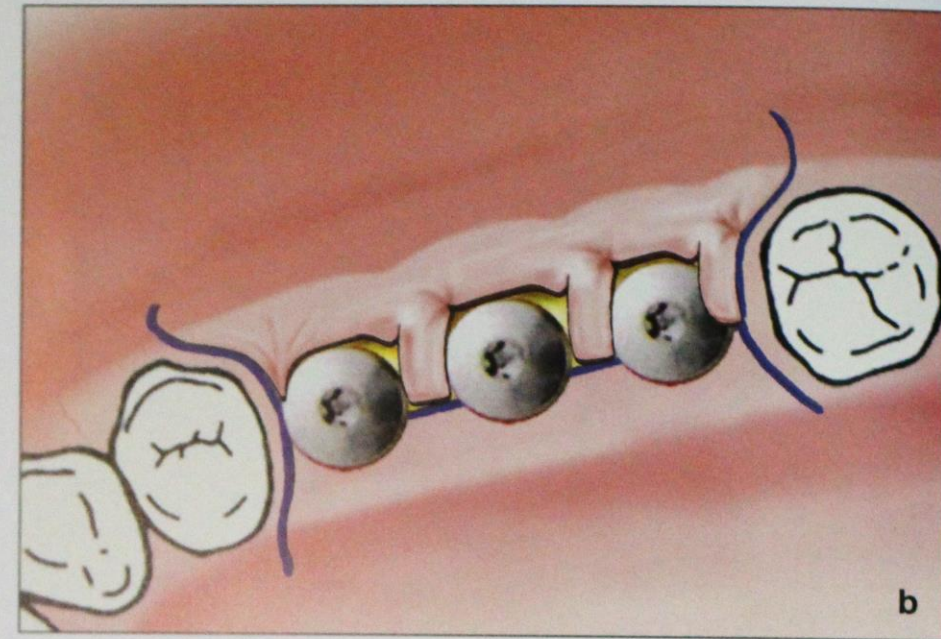
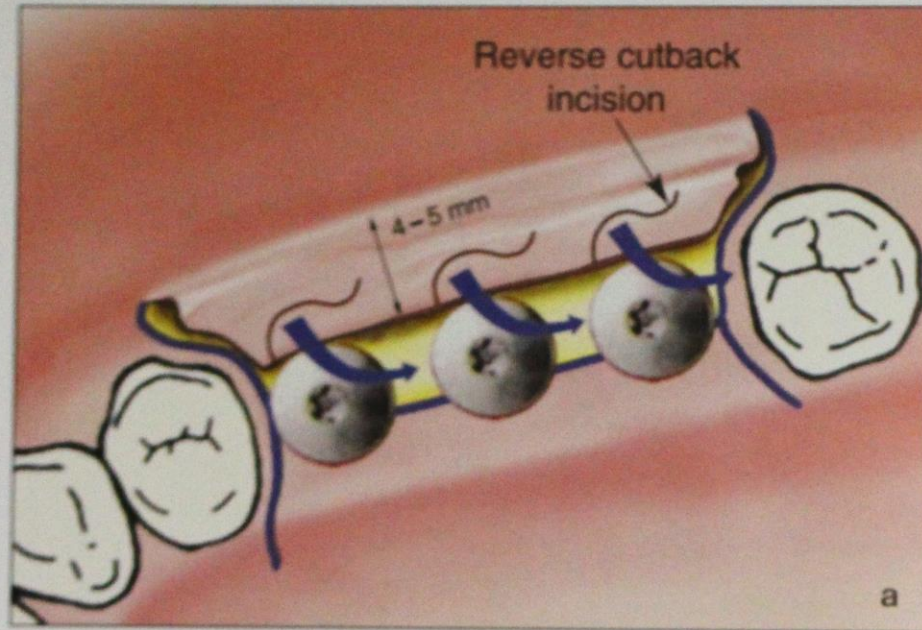


# Z-plasty papilla reconstruction

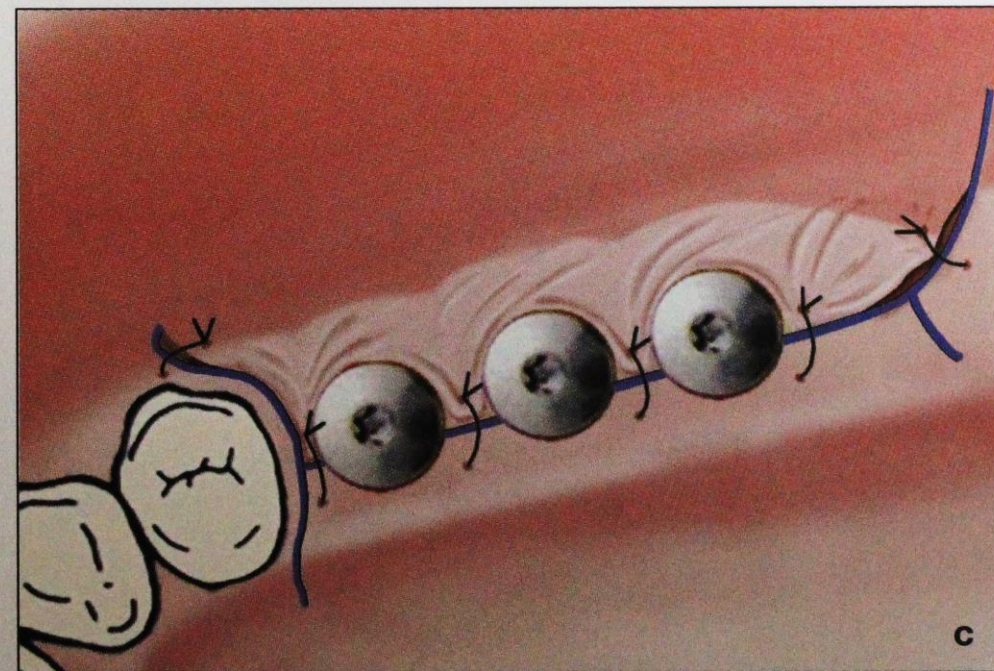
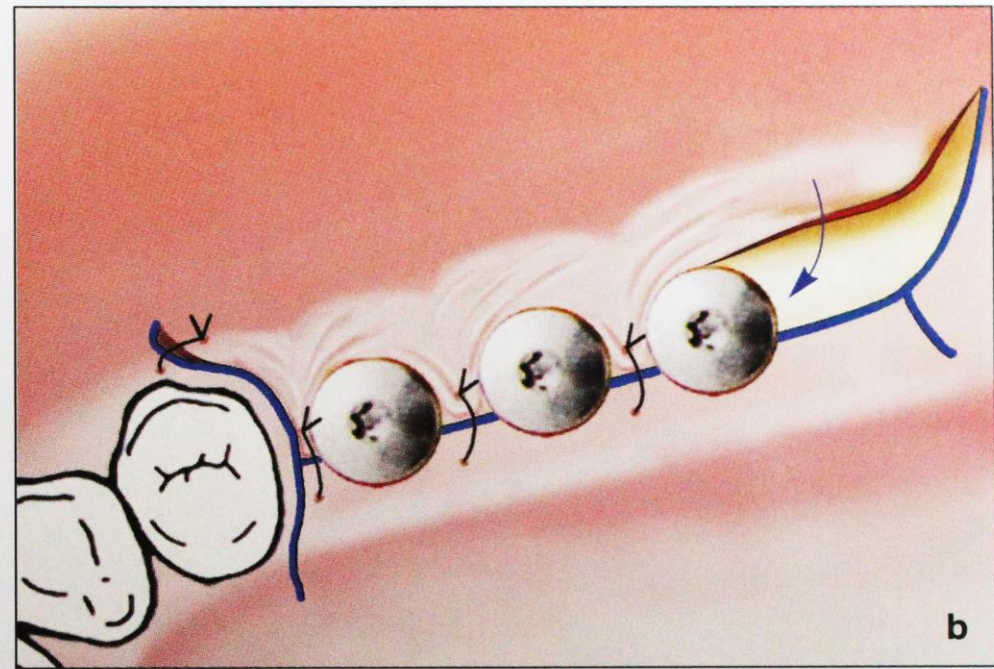
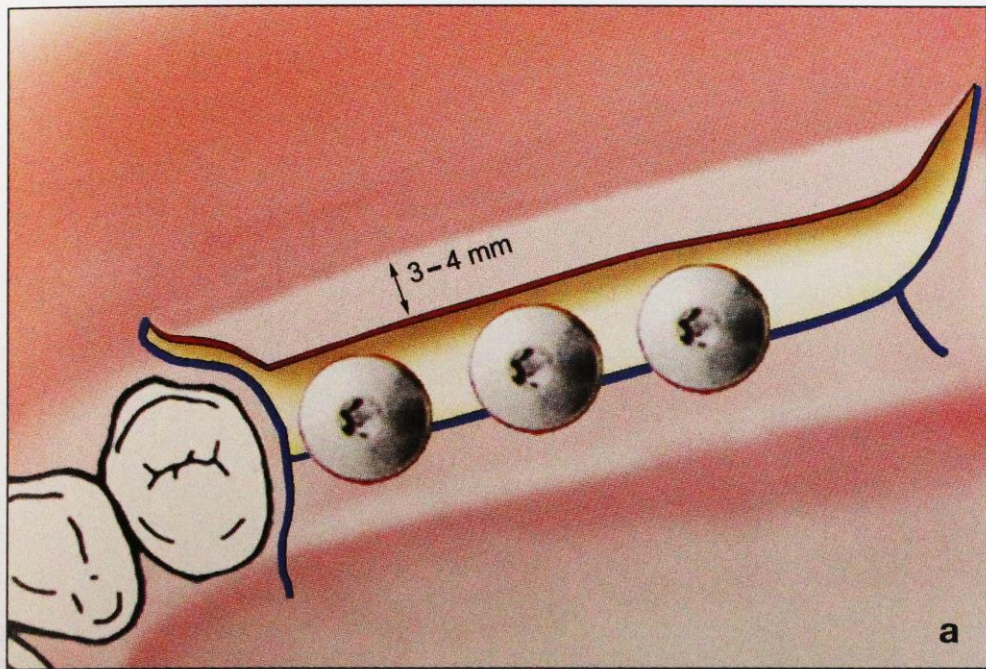
- ▣ Use a #12B blade to make incisions
- ▣ Elevate soft tissue carefully with Woodson elevator
- ▣ Remove cover cap, rinse, dry and either insert custom Atlantis abutment and temporary or Contour Healer custom abutment
- ▣ Rotate and tuck papilla's into interproximal spaces and suture with interrupted 4-0 chromic gut
- ▣ Apply tissue glue if needed to seal tissue into position



**Figs 3-11a to 3-11c** (a) When the apicocoronal dimension of attached tissue remaining on the buccal flap is 5 to 6 mm, resective contouring can be used to obtain circumferential adaptation around emerging implant structures. Attached tissue is taken from the top of the ridge and moved in a buccal direction. The tissue contouring begins adjacent to the anteriormost implant. A no. 15C scalpel blade is used to perform a precise gingivectomy corresponding to the size and shape of the emerging implant. (b) After re-adapting the contoured tissue around the anteriormost implant, tissue is resected in a sequential fashion moving in a distal direction. (c) The flap is then apically repositioned around the emerging implant structures with sutures placed in each inter-implant area. The curvilinear releasing incisions also are closed with interrupted sutures.



**Figs 3-12a to 3-12c** (a) When the apicocoronal dimension of attached tissue remaining on the buccal flap is 4 to 5 mm, the papilla regeneration technique can be used to obtain circumferential closure of attached tissue around the permucosal implant elements. Attached tissue is taken from the top of the ridge and moved in a buccal direction. Pedicles are created in the margin of the buccal flap adjacent to the emerging implants. The thickness of the pedicles corresponds to the size of the inter-implant space. (b) The pedicles are rotated into the inter-implant spaces. Extension of the incision away from the flap margin in the form of a "reverse cutback" facilitates passive positioning and advancement of the pedicles to the interdental spaces. (c) The flap is re-adapted and secured to obtain circumferential adaptation around emerging implant structures. Figure-eight or interrupted sutures are placed so as to avoid creating tension in the pedicles, which could embarrass their circulation.



**Figs 3-13a to 3-13c** (a) When the apicocoronar dimension of attached tissue remaining on the buccal flap is 3 to 4 mm, lateral flap advancement is indicated to obtain circumferential closure of attached tissue around the permucosal implant elements. Tissue is taken from the top of the ridge and moved in a buccal direction. (b) Resective contouring is avoided to preserve the apicocoronar dimension of the attached buccal tissues. The flap is apically repositioned and advanced in a mesial direction. The closure begins at the mesial aspect of the anteriormost implant and progresses in a distal direction around each implant. (c) The attached tissues distal to the implant site are repositioned in a mesial direction to ensure circumferential adaptation around the emerging implant components.

# Contour Healer anatomically correct healing abutments

A close-up photograph of a white, dome-shaped dental abutment with a threaded metal base, set against a blue sky with clouds. The abutment is shown from a three-quarter perspective, highlighting its smooth, rounded top and the precision of its connection point.

Home | Products » | STORE | About Us | FAQs | Contact |

## CONTOUR HEALER

THE SUPERIOR CHOICE FOR RESTORATIVE HEALING

### Welcome

The Contour Healer, LLC product line includes pre-manufactured dental abutments intended to serve as a temporary dental prosthesis during the healing process until a permanent crown is fabricated. They are directly connected to the endosseous dental implant by a screw. These devices are single-use and available to fit multiple platforms. [Read more >](#)

### The Contour Healer

The Contour Healer, LLC product line includes pre-manufactured dental abutments intended to serve as a temporary dental prosthesis during the healing process until a permanent crown is fabricated. They are directly connected to the endosseous dental implant by a screw. These devices are single-use and available to fit multiple platforms.

[Read more](#)

### Indications For Use

The Contour Healer Temporary Abutment is intended for use with root-form endosseous dental implants to aid in prosthetic rehabilitation. The abutment is a provisional restoration that aids in creating an esthetic emergence through the gingiva during the healing period. The device is intended for single restorations

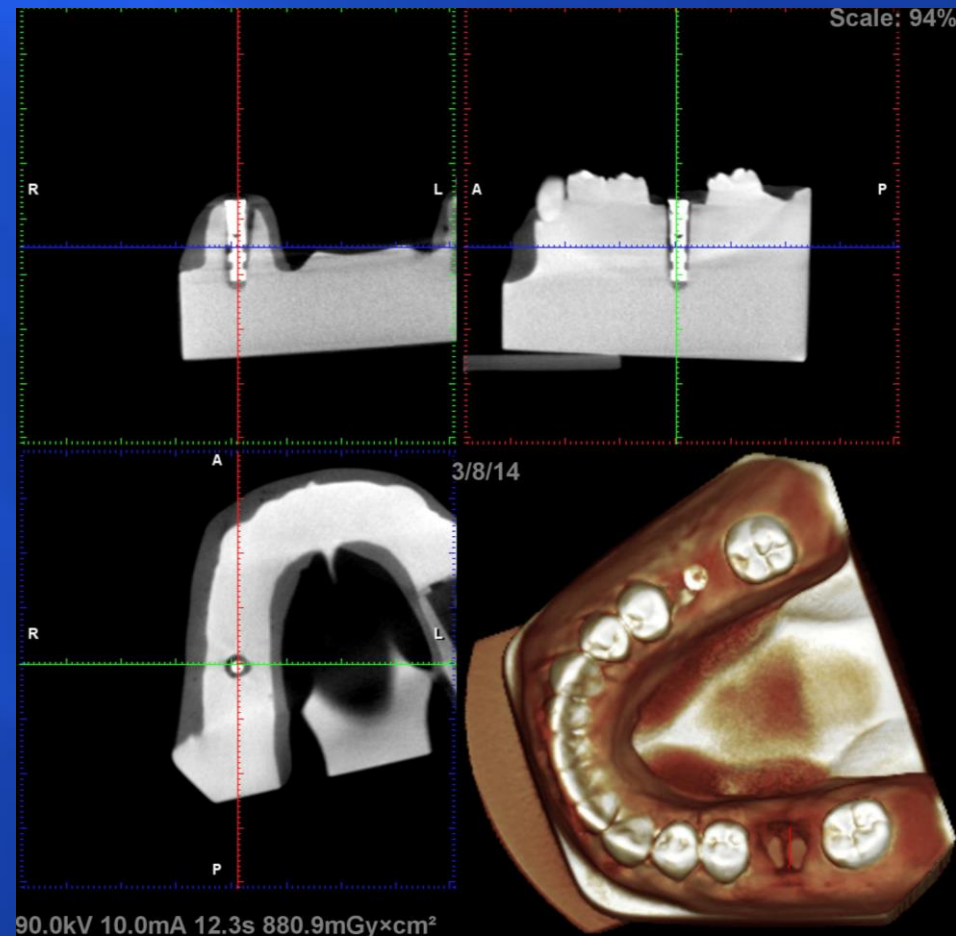
[Read more](#)

“ *The Contour Healer creates the ideal emergence with a simple, easy to use abutment. The impressions are flawless, and the lab can easily create esthetic crowns with no worry of tissue impingement.* ”

- Bryan M. Konikoff, D.D.S., M.S.

### Products

# Surgical 2<sup>nd</sup> stage uncovering of implant #30 with Z-Plasty reconstruction of the papilla & insert of custom abutment



CONTOUR H

Zimmer

BioHoriz

Type RP

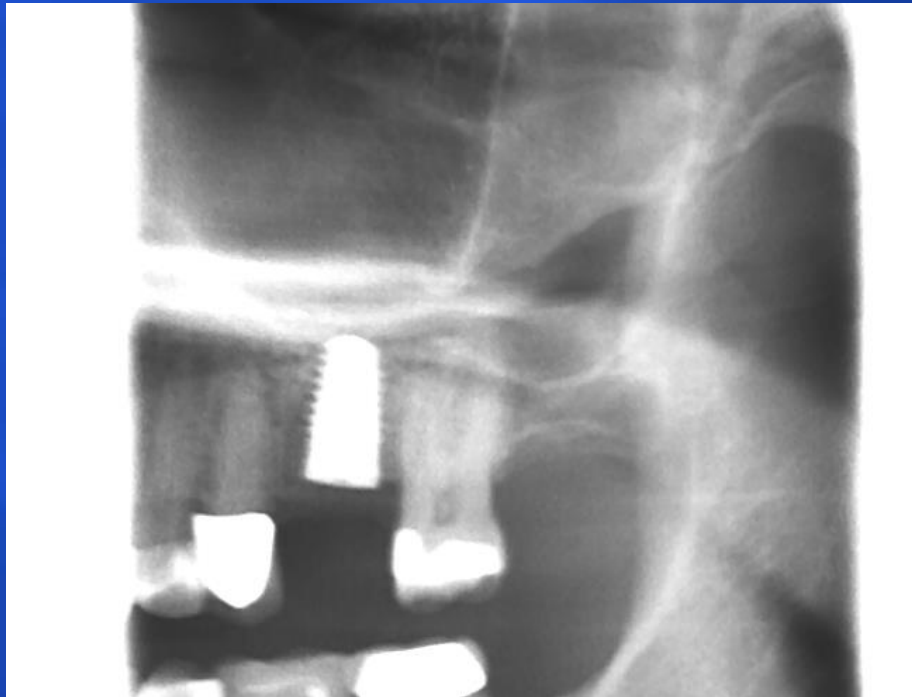
NON-STERILE

US PATENT #0611,1485

2

i LOT

Surgical 2<sup>nd</sup> stage uncovering of implant #30 with Z-Plasty reconstruction of the papilla & insert of custom abutment #30 with Z-Plasty reconstruction of the papilla & insert of custom abutment

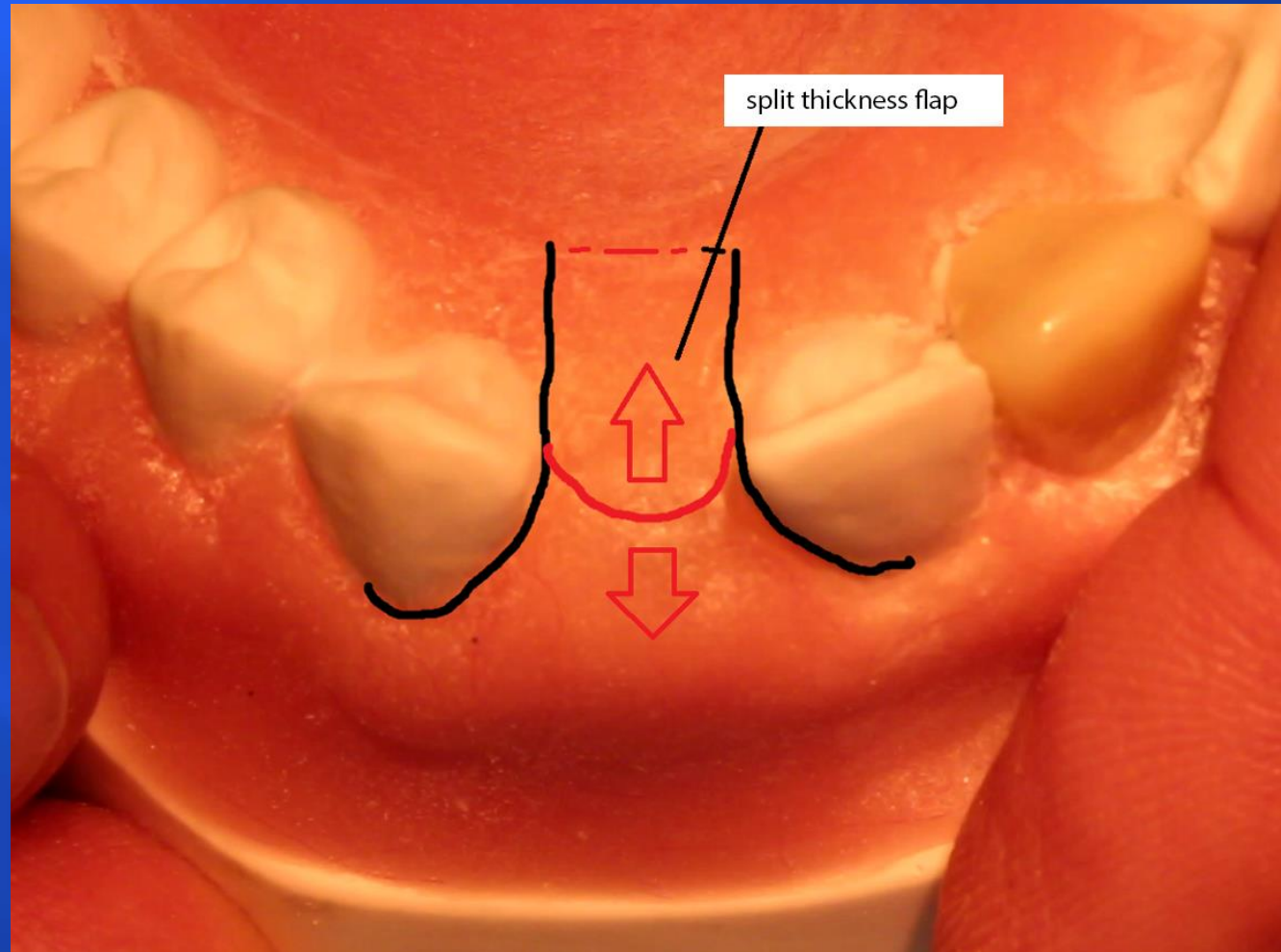


(Video)

# Surgical 2<sup>nd</sup> stage uncovering of implant #10 with palatal roll connective tissue graft

- ▣ Outline procedure on implant model or paper if an impression was not taken at the time of implant placement
- ▣ Assess the exact location of the Muco-gingival junction and how much attached mucosa is present, best if > 4mm
- ▣ Assess if additional graft or contour is needed on buccal

# Surgical 2<sup>nd</sup> stage uncovering of implant #10 with palatal roll connective tissue graft



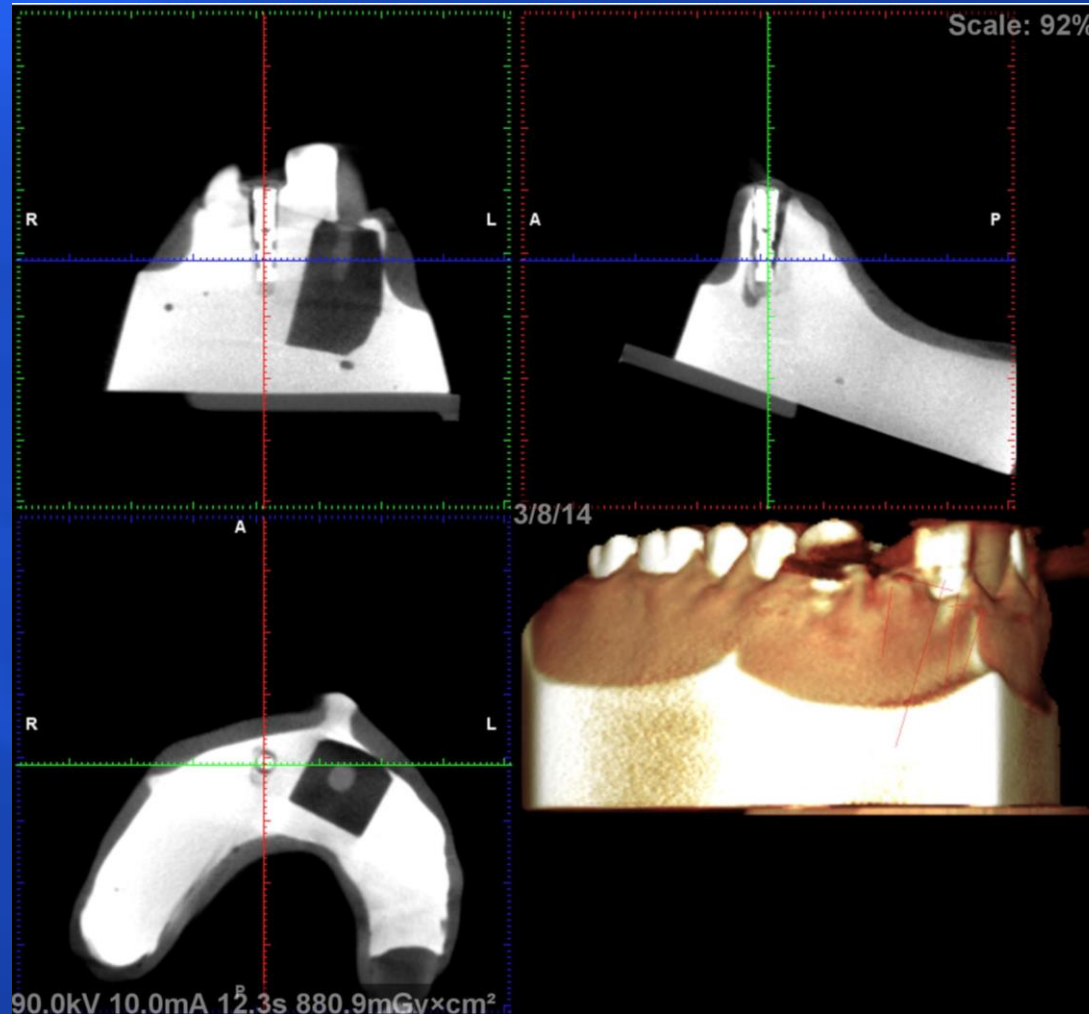
# Surgical 2<sup>nd</sup> stage uncovering of implant #10 with palatal roll connective tissue graft

- ▣ Make incisions with double edged micro blade
- ▣ Carefully note where incisions are partial thickness and full thickness.
- ▣ Start with all full thickness incisions to get a feel of thickness of the tissues, especially the palate.
- ▣ Make horizontal split thickness incision and carry slowly under the tissue with gentle elevation of the split thickness flap down to base on palatal vestibule
- ▣ Release periosteal split thickness graft and elevate forward using curved end of Woodson or a spoon curette

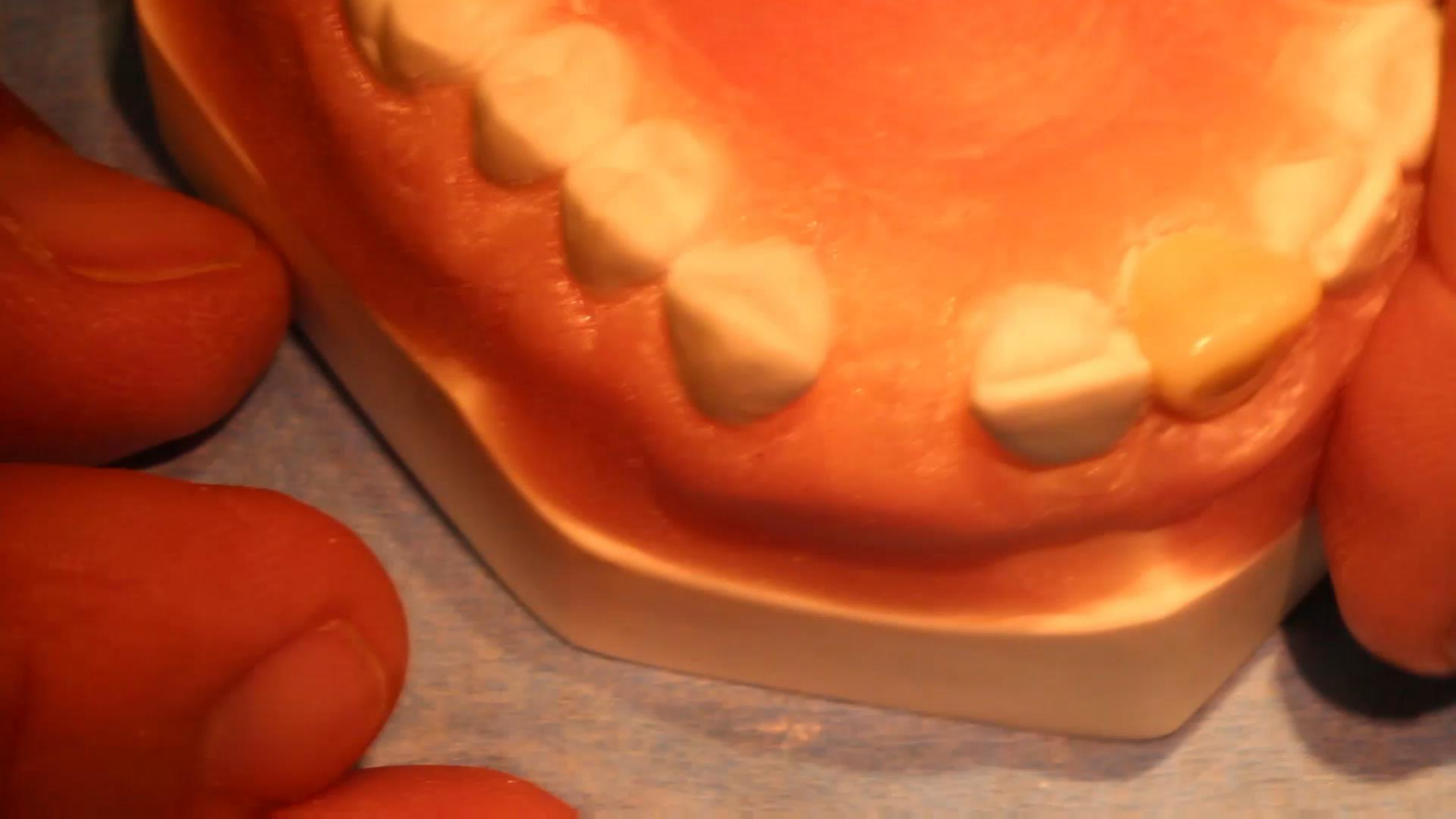# Surgical 2<sup>nd</sup> stage uncovering of implant #10 with palatal roll connective tissue graft

- ▣ Continue to elevate soft tissue forward (buccally)
- ▣ Undermine/dissect down buccal plate to above M-G junction
- ▣ Remove implant cover cap and insert abutment, usually final custom Atlantis abutment or custom plastic abutment
- ▣ Roll elevated palatal sub-epithelial tissue under buccal tunnel flap
- ▣ Suture with interrupted sutures, usually 4-0 chromic gut or 4-0 Vicryl (will require removal) or new Vicryl Rapide (7-10 day)
- ▣ Optional seal with tissue glue

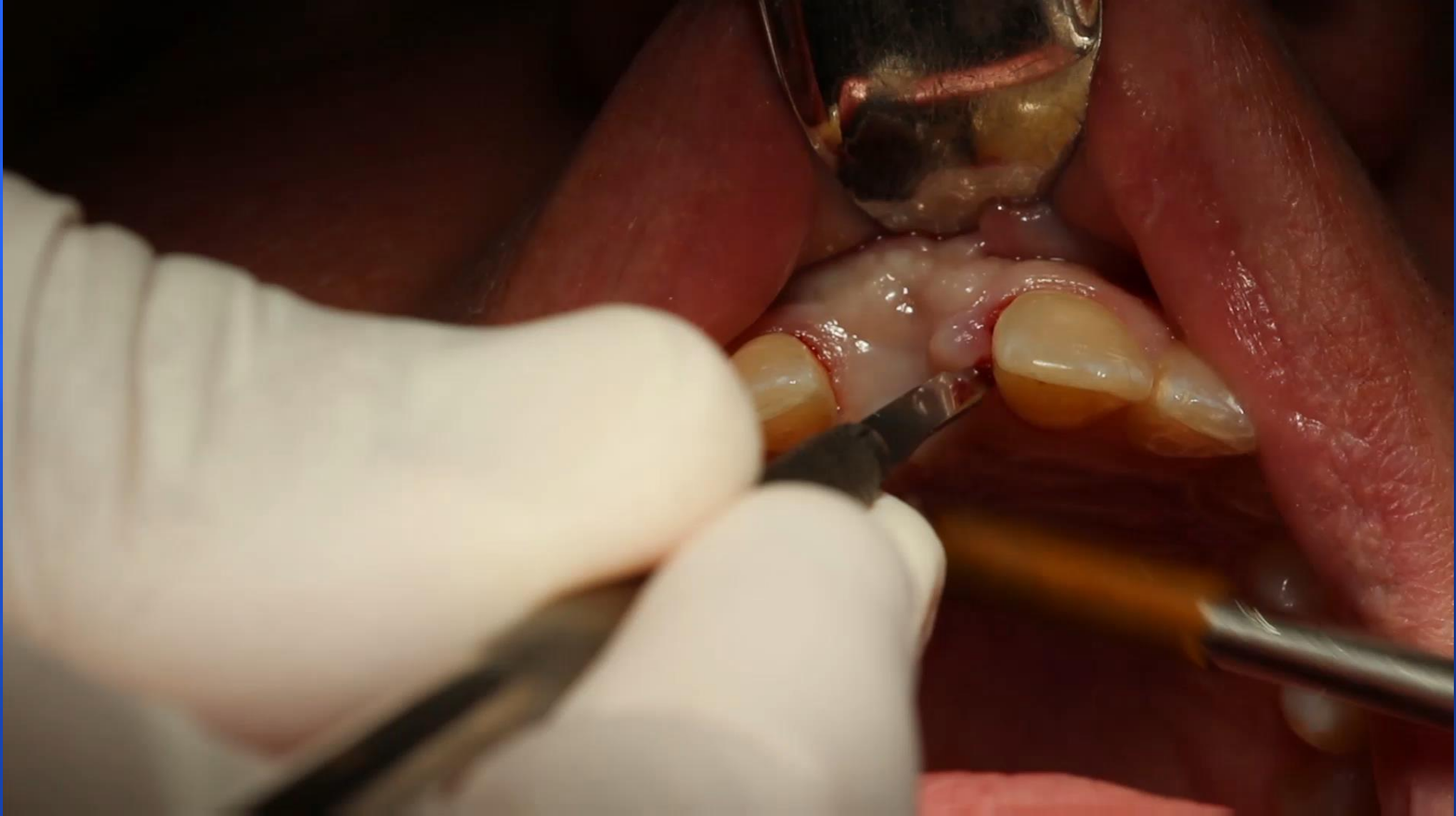# Surgical 2<sup>nd</sup> stage uncovering of implant #10 with palatal roll connective tissue graft



(Video)



# Surgical 2<sup>nd</sup> stage uncovering of implant #10 with palatal roll connective tissue graft



# Post Operative Care

- ▣ Pain medications-usually Motrin 800 mg pre-op, if not immediately post-op Rx T#3 or Norco 7.5/325
- ▣ Keflex 500 mg QID (Cleocin 150 QID) for 10 days
- ▣ Over the counter sinus medications if the sinus floor has been elevated
- ▣ Ice/gel packs along with intra oral cold-slurpees, ice cream, ice chips
- ▣ Lightly brush area and rinse with salt water for first week, no flossing till sutures fall out

# Post Operative Care

- ▣ Irrigation syringe starting on the 3<sup>rd</sup> day with salt water, after one week, move up to a mixture of 6 oz. of warm water, 1 oz. of hydrogen peroxide, and 1 oz. of mouthwash
- ▣ After 6 weeks move up to a water pik using the water, peroxide and mouthwash mixture at least at bedtime